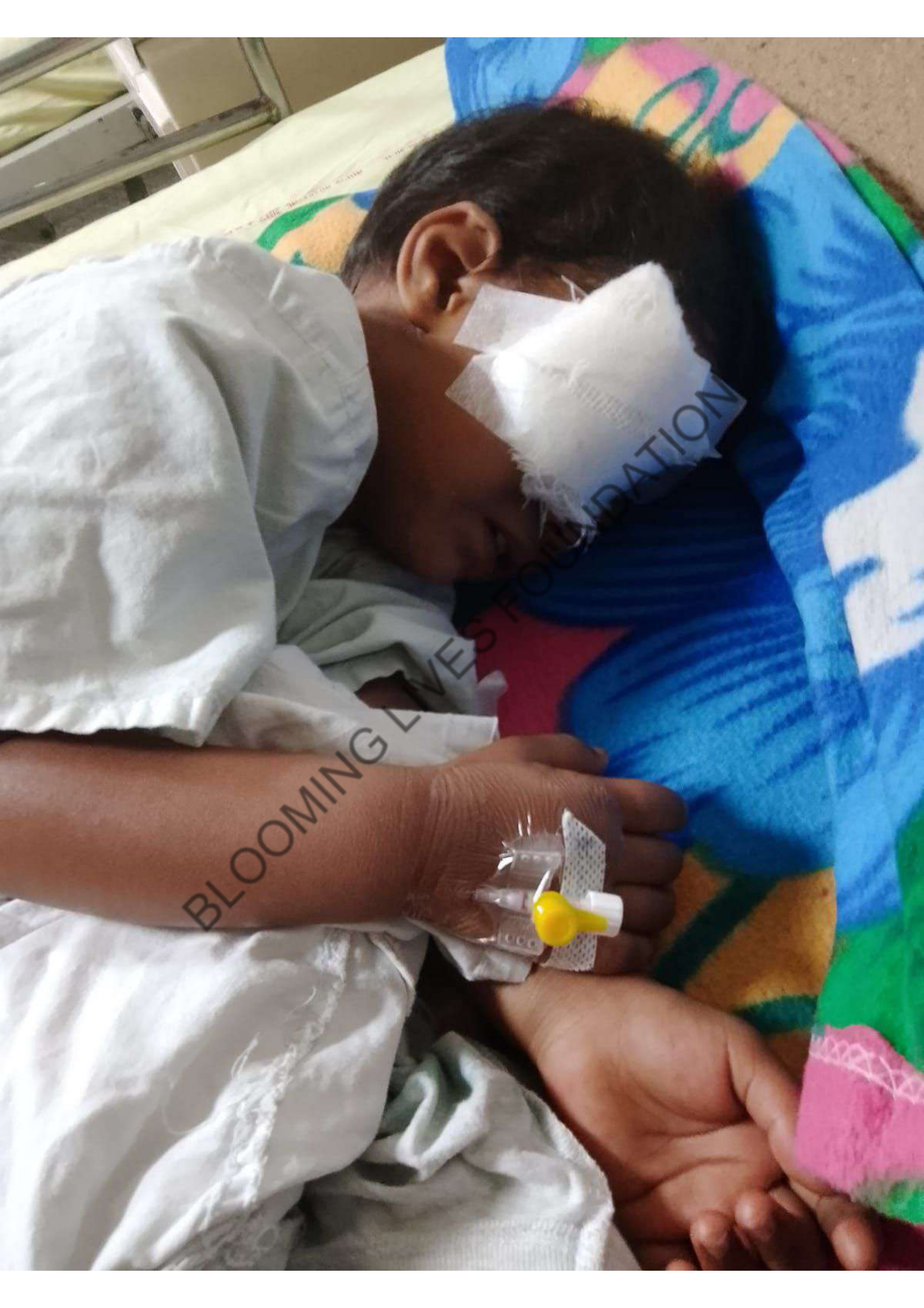



BLOOMING LIVES FOUNDATION



# Histopathology Report

## Ocular Pathology

Dr. Rajendra Prasad Centre for Ophthalmic Sciences

All India Institute of Medical Sciences

Ansari Nagar, New Delhi - 110029, India

Name of the Patient: Mahima

Lab Reference No. : 26-546

Age : 2.5 Years Sex : Female

Received on : 2/4/2026

UHID No. : 108662073

Date of Report : 7/4/2026

Ward IB Bed No. : 140

Unit Incharge : Prof. Bajaj

Nature of the Material Enucleation.  
Submitted :

Report :

- Enucleated right eye ball.
  - Poorly differentiated retinoblastoma, right side (post chemotherapy) (LTD-15mm).
  - The tumor shows extensive calcification, subretinal fluid with retinal pigment laden macrophages and cholesterol clefts.
  - The iris, ciliary body and choroid are free of tumor.
  - The optic nerve shows extensive post laminar optic nerve infiltration.
  - The resected margin of the optic nerve is free of tumor.
- AJCC - ypT3b NoMo.

(Post chemo)

Reported By



# Histopathology Report

## Ocular Pathology

Dr. Rajendra Prasad Centre for Ophthalmic Sciences

All India Institute of Medical Sciences

Ansari Nagar, New Delhi - 110029, India

Name of the Patient: Mahima

Lab Reference No. : 26-546

Age : 2.5 Years Sex : Female

Received on : 2/4/2026

UHID No. : 108662073

Date of Report : 7/4/2026

Ward IB Bed No. : 140

Unit Incharge : Prof. Bajaj

Nature of the Material Enucleation.  
Submitted :

Report :

- Enucleated right eye ball.
  - Poorly differentiated retinoblastoma, right side (post chemotherapy) (LTD-15mm).
  - The tumor shows extensive calcification, subretinal fluid with retinal pigment laden macrophages and cholesterol clefts.
  - The iris, ciliary body and choroid are free of tumor.
  - The optic nerve shows extensive post laminar optic nerve infiltration.
  - The resected margin of the optic nerve is free of tumor.
- AJCC - ypT3b NoMo.

(Post chemo)

Reported By

26-216



Dr. Rajendra Prasad Centre For Ophthalmic Sciences  
ALL INDIA INSTITUTE OF MEDICAL SCIENCES (AIIMS), New  
Delhi, 110029

Discharge Report  
PROVISIONAL DISCHARGE CERTIFICATE

*REGD PLEASE LAMWATS*

UHID :	108662073	Cr No:	R-014774-26
Name:	Miss. MAHIMA MAHIMA	Department:	R. P. Centre (Eye Centre)
Age/Sex:	2 years 5 more 14 days / Female	Unit:	Unit-V
Ward Name:	RPC 1B	Bed No.:	140
Address:	CHANDARPUR, BARWA CHAPRAWAN, KUSHINAGAR, UTTAR PRADESH, Pin:274306, INDIA	<div style="border: 1px solid black; padding: 5px;">           Drug Allergy, if any :- <input type="checkbox"/>  <i>ML</i>            108662073         </div>	
Mobile No:	8429928783		
Date of Admission:	27/03/2026 10:50:25 AM		
Date of Discharge :	03/04/2026 08:24:00 AM		

ICD Code: .D47.0  
 ICD Description: Histocytic and mast cell tumours of uncertain and unknown behaviour

Diagnosis  
 RE GROUP E STAGE 3 A T4N0M0+X  
 LE FELLOW EYE

Investigation	Systemic	NO SI	Ocular	VA RE NOT FOLLOWING LIGHT LE FOLLOWS OBJECT C 6/12 AT 50CM
---------------	----------	-------	--------	---

Treatment/Operative Procedure	Surgeon	DR. ARCHANA / DR. SREYOSI	Surgery	RE ENUCLEATION PLUS PRIMARY IMPLANT UNDER GA <i>Implant size : 20 mm        ON stump : 18 mm</i>
	Date	02/04/2026		

Condition at Discharge	Vision	RE ENUCLEATED EYE	IOP	RE ENUCLEATED EYE
	Anterior Seg.	RE ENUCLEATED EYE WATERY DISCHARGE WOUND OPPOSED AND SUTURES INTACT	Posterior Seg.	RE ENUCLEATED EYE

Advice During Discharge:	Oral	SYP PCM 5ML/125 -- 3 ML <i>BD X 3 days</i> SYP DIGENE 1 TSP OD BBF <i>- 1 tsp qd</i> SYP AUGMENTIN 5ML/228 MG -- 3 ML FOR 5 DAYS	Topical Position	BE E/D REFRESH TEARS 6 TIMES <i>6/12</i>
Follow Up	DR. ARCHANA IN OPD 32 AT 9AM ON 10/04/26			

*LE-EVA done  
 C:D=0.2:1  
 NRR Healthy  
 FR sharp  
 no lesion noted.*

*cold compression  
 10/4/26  
 (32) 9AM*

*Prepared By: Dr. ASHAY K S  
 Signature Of Senior Resident*

AIIMS PRESS...  
 MEDICINE RECEIVED  
 NAME: *(100) 3/4/26*

Date & Time



डा. बी. आर. अम्बेडकर संस्थान रोटरी कैंसर अस्पताल  
Dr. B.R. Ambedkar Institute Rotary Cancer Hospital

अ.

OPR-6

शरीरमाद्यं खलु धर्मसाधनम्

अस्पताल नं.

DR. B.R.A. IRCH, AHMS, NEW DELHI

IRCH No. 355628

Reg. Date-09/02/2026

REMISES

Clinic Paediatric Medical Oncology Clinic

Clinic No. 2025/8492

Deptt. MEDICAL ONCOLOGY

General



एकक/Unit

नाम

UHID-108662073

विभाग/Dept.

Name MAHIMA

n. No.

नाम/ Name

D/O- AMARJEET YADAV

Sex/Age F/2Y

तिथि / Date of Birth

Phone No. 8429928783

Room Board Room (Shift Afternoon)

Address CHANDARPUR BARWA CHHAWANI, KUSHINAGAR, UTTAR PRADESH, Pin:274306, INDIA

निदान/ Diagnosis

Rb - S7-V1

दिनांक/ Date

16/4/26

उपचार/ Treatment

Ref to RT-PCR

मिटर 5  
257-13

BLOOMING LIVES FOUNDATION  
Suneeza Bhat

17/4/26

To register & Ro OPD

↓ Dr. Anit Bhatnagar

on 8/5/2026 R#13

FRIDAY, IRCH f sepra

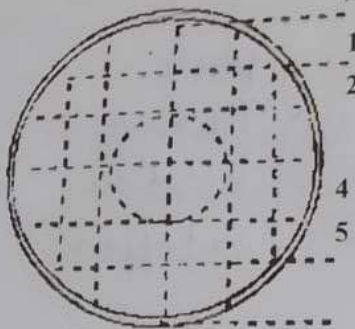
RIGHT

CORNEA

- Size, Shape
- Surface, Transparency
- Ulcer
- Vascularization
- Opacity
- Degeneration
- Dystrophy
- Sensation
- Thickness

Ⓢ size, shape clear  
 No ulcer  
 No vascularisation.  
 sensation intact

F E D C B A



No nodules / Ectasia

VH<sub>3</sub>  
No cells

Blown  
No coloboma

SCLERA

- Shape, Vessels
- Nodules, Ectasia

ANTERIOR CHAMBER

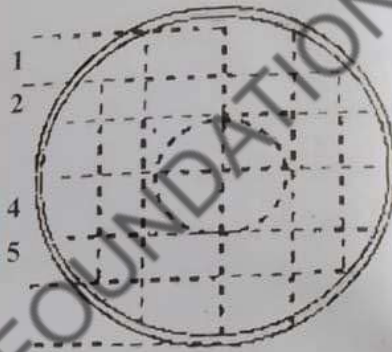
- Depth
- Regularity
- Contents
- Angle of A.C.

IRIS

- Colour Pattern
- Coloboma
- Nodules Vascularization

Ⓢ size, shape clear  
 No ulcer  
 No vascularisation  
 sensation intact

A B C D E F



No nodules / Ectasia

VH<sub>3</sub>  
No cells

Blown  
No coloboma

PUPIL

- Size
- Shape
- Position
- Synechia
- Reaction to direct light
- Consensual
- Accommodation

LENS

- Transparency
- Position
- Capsule

VITREOUS

- State
- Opacities

INTRAOCULAR

- Digital
- Instrumental, Schein
- Applanation

BIOMICROSCOPY

FINDINGS (D)

VISION AND CRITICAL REVIEW

दिनांक - Date

उपचार - Treatment

Next  
Date of  
Cycle

Old OP date: 19 @ 2PM

Dr Nymisha

*[Signature]*

27/3/26

Δ - EORB (R)

• Pt. completed 6 chemo cycles

POA  
27/3/26  
Ward 1B  
7:30AM

Date of enucleation - 27/3/26

No active intervention at present.

*[Signature]*

BLOOMING LIVES FOUNDATION

नेत्र ईश्वरीय सर्वश्रेष्ठ उपहार है जिनका मनुष्य जीवन में दान करना परमश्रेष्ठ है।

इनकी पूर्ण रक्षा कीजिए ताकि ये आपकी रक्षा कर सकें।

Eyes are God's most precious gift to man kind and eye donation is the most noble deed.

Take full care of them so that they can take care of you.

Date

Informant - Father  
Reliable

COMPLAINTS WITH DURATION

- 1.
- 2.
- 3.
- 4.
- 5.

- 4/0 whitish opacity in (R) x 6 months.  
(leukocoria)

HISTORY OF PRESENT ILLNESS

The parents give 4/0 whitish opacity in (R) since 6 months which was noticed accidentally, and took child to Gorakhpur pvt Hospital where ultrasound was done and told tumor in (R) eye & referred to Banaras where CT scan was done

confirmed (R) intraocular RBE VH. Not following subject advised Neoadjuvant chemo  
↓  
Enucleation ↓ GA  
patient was referred to RPC.

HISTORY OF PAST ILLNESS

No SI.

Presented to RPC in 7/10/25

T<sub>1</sub> mild hyperintense T<sub>2</sub> Hypointense  
12x18x17mm ± minimal extension post contrast enhancement of 11mm noted scleral optic chiasm (N) + Breech noted

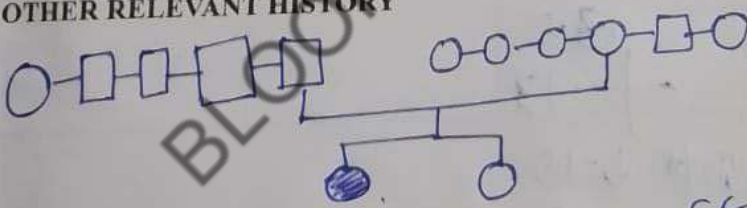
HISTORY OF PREVIOUS OPERATION

- Full Term, BW - 2 1/2 kg, NVD
- No NICU Admission
- No Developmental Delay
- No family 4/0 similar complaints.

? EORB.

Referred to medical oncology for EBRT

OTHER RELEVANT HISTORY



7/11/25 → VEC 1st cycle.

8/11/25 → 2nd cycle.

28/11/25 → 3rd cycle

CE-MRI repeated. NRC done

Subtle thickening of (R) ON still present along ± enhancement

Definite reduction in size (P)

31/12/25 4th cycle

21/1/26 5th cycle

2/3/26 6th cycle.

got admitted for Enucleation (R)



EYE BALLS

- Size, Shape
- Position
- Direction
- Movements
- Cover test
- Convergence

EYE LIDS

- Position
- Palpebral aperture
- Movements, Skin
- Margins, Cilia
- Glands, Canthi

DRAINAGE SYSTEM

- Puncta, Lac. Sac.
- Lac. Gland
- Nasal check up

CONJUNCTIVA

- Discharge, congestion
- Follicles
- Scars
- Bulbar
- Palpebral
- Fornices
- Plica semilunaris
- Caruncle
- F.B.

Pulse  $\frac{114}{\text{mt}}$   
 Resp.  $\frac{22}{\text{mt}}$

B.P. cuff not available

Temperature  $\ominus$

Anaemia  $\text{WNL}$

Any other relevant finding

(C.V.S., Resp. G.I. & C.N.S. system)

No LN enlargement

WNL

GENERAL PHYSICAL EXAMINATION

- General Health  $\frac{1}{\text{good}}$
- Oral hygiene  $\frac{1}{\text{good}}$
- Parotids  $\frac{1}{\text{WNL}}$
- Mucous Membranes  $\frac{1}{\text{WNL}}$
- Sleep

SYSTEMIC EXAMINATION

VISUAL ACUITY	DISTANCE		NEAR	
	Right	Left	Right	Left
Keel eye	Not following targets	Candiff 6/12 at 50cm		-
glasses				
glasses				
	No Strab for med			

+3.5  
+1.5

Utopia: 6-1.5

+2  
+3.5

+2DS | to +4 x 90°  
 Compd hypermetropic  
 Astigmatism

डा० राजेन्द्र प्रसाद नेत्र विज्ञान केन्द्र  
Dr. Rajendra Prasad Centre for Ophthalmic Sciences  
A.I.I.M.S.  
Ansari Nagar, New Delhi-110029

Section .....  
Sr. Resident *Dr. Tushar* Jr. Resident *Dr. Satish*

*Prof. Ms. Bajaj*

Dr. Rajendra Prasad Centre for Ophthalmic Sciences	
UNIT: OPHTHALMOLOGY	DATE: 17/01/2018 10:45 AM
CR No. 8429928783	Ward No. RFC 1B
Name: MISS. MAHIMA MADHMA	Bed No: 140
Ref. In-charge: Dr. M. S. Bajaj	Unit: 140
ACCOUNTS: EL-923M/2017/6 RS 140	

Sp. Clinic No. \_\_\_\_\_ Ward / Bed No. **140**

Age \_\_\_\_\_ Sex \_\_\_\_\_ Nationality \_\_\_\_\_

Family Income \_\_\_\_\_ Single / Married \_\_\_\_\_

Number of Family Members (including self) \_\_\_\_\_

Occupation \_\_\_\_\_

O.A. \_\_\_\_\_ Time \_\_\_\_\_

O.D. \_\_\_\_\_ Time \_\_\_\_\_

Previous Admission / CR No. \_\_\_\_\_

Admission-Routine / Emergency / EHS / \_\_\_\_\_

Permanent Address \_\_\_\_\_

Local Address \_\_\_\_\_

Tele No. - **84 29 92 87 83**

DIAGNOSIS	Primary	2nd	3rd	Code No.
Right Eye Not following light	(R) Group E	stage III A		1) No SI 2) 3)
Left Eye Follows object Cardiff 6/12 m at 5cm	(L) fellow eye			1) 2) 3)
Medical / Operation Treatment				

Result: Cured / Relieved / Stationary / Failure

Photographs No. \_\_\_\_\_

Histopath Report No. *wt - 10.5 kg*

Signature \_\_\_\_\_

LOCAL EXAMINATION

RIGHT

EYE BALLS

Size, Shape

Position

Direction

Movements

Cover test

Convergence

EYE LIDS

Position

Palpebral aperture

Movements, Skin

Margins, Cilia

Glands, Canthi

DRAINAGE SYSTEM

Puncta, Lac. Sac :

Lac. Gland

Nasal check up

CONJUNCTIVA

Discharge, congestion.

Follicles

Scars

Bulbar

Palpabral

Fornices

Plica semilunaris

Caruncle

F.B.

(N) size, shape  
Axial



No { Ptosis  
Trichiasis  
Ectropion  
Entropion

Puncta opposed to  
Globe  
No regurgitation

No { Discharge  
congestion  
follicles  
scar  
FB

(N) size, shape  
Axial



No { Ptosis  
Trichiasis  
Ectropion  
Entropion

Puncta opposed to  
Globe  
No regurgitation

No { Discharge  
congestion  
follicles  
scar  
FB

BLOOMING LIVES FOUNDATION

# ब. रो. वि. कार्ड O.P.D. Card



अनुभाग व दिन  
Section and Day V  
मंगलवार व शुक्रवार  
Tuesday & Friday

कमरा नंबर  
Cabin No.

डा. राजेन्द्र प्रसाद नेत्र विज्ञान केन्द्र



UHID: 108662073  
ABHA:  
Dept No: 20250050120040

संख्या / Queue: 0  
कमरा / Room: 33  
Unit-V  
RPC OPD

MAHIMA

Dr. SWATI PHULJHELE

D/O AJAY YADAV  
1Y 11M 21D / F

TUE, FRI  
मंगल, शुक्र

BARAWA 52 KUSHINAGAR, UTTAR  
PRADESH, Pin: 274149, INDIA  
Mob: 8429928783  
Follow Up Patient

Registration time:  
10/10/2025 08:48:32 AM

बजाज का एकक  
Bajaj's Unit

आयु  
Age

पता  
Address

दिनांक DATE	निदान DIAGNOSIS	उपचार Treatment
11 OCT 2025	(P) ?? EMB	<p>उपचार Treatment</p> <p>MD s/o Temporal nasal mass extending dist dist. Nasal mass splc. @ thickening ~ learn</p> <p>Adv N/A discussion + by sangay shal sr.</p> <p>Wed (53) 10:30 AM</p> <p>Kindly accommodate in dharam shala</p> <p>Turkey sh</p> <p>Turkey CM</p>

कृपया इस कार्ड को सुरक्षित रखें तथा अस्पताल में दिखाने के समय हर वक्त साथ लायें।

Kindly keep this Card safely and bring it on your follow-up visits.

- धूम्रपान निषेध
- कूड़ा कर्कट केवल कूड़ेदान में ही डालें
- थूकिये नहीं
- No Smoking
- Use Dustbin
- No Spitting

(43)

Suture 4-0 Silk (Code: W-894)	Rs. 90/-
Suture 5-0 Ethibond Spatulated Double Needle	Rs. 72/-
Suture 6-0 Vicryl (Code: NW 2670)	Rs. 300/-
Suture 7-0 Vicryl (Code: NW 2561)	Rs. 322/-
Suture 8-0 Spatulated	

Ali optical

दिनांक - Date

उपचार - Treatment

Silicon implants 16, 18, 20

(56)

PMMA implants 16, 18, 20

✓ medium } → (RE) Conformer  
 ✓ large }

BLOOMING LIVES FOUNDATION

नेत्र ईश्वरीय सर्वश्रेष्ठ उपहार है जिनका मनुष्य जीवन में दान करना परमश्रेष्ठ है।  
 इनकी पूर्ण रक्षा कीजिए ताकि ये अपनी रक्षा कर सकें।

LOCAL EXAMINATION

**EYE BALLS**  
 Size, Shape  
 Position  
 Direction  
 Movements  
 Cover test  
 Convergence

**EYE LIDS**  
 Position  
 Palpebral aperture  
 Movements, Skin  
 Margins, Cilia  
 Glands, Canthi

**DRAINAGE SYSTEM**  
 Puncta, Lac. Sac :  
 Lac. Gland  
 Nasal check up

**CONJUNCTIVA**  
 Discharge, congestion  
 Follicles  
 Scars  
 Bulbar  
 Palpabral  
 Fornices  
 Plica semilunaris  
 Caruncle  
 F.B.

	NEAR		DISTANCE		USUAL ACUITY
	Right	Left	Right	Left	
Visual acuity					6/12 at 6m
Conjunctiva					Cardiff 6/12 at 6m
Cornea					
Lens					
Retina					
Optic disc					
Visual field					

+2DS / +0.50 x 90°  
 Central hypermetropic  
 Astigmatism

+1.5  
 +0.5  
 +2.0  
 IOP: 1-1.5

No streak formed

No LR enlargement

(C.V.S., Resp. G.I. & C.N.S. system)  
 WNL

Any other relevant finding

B.P. cuff not available

Temperature ⊖

Anaemia WNL

Pulse 114 /mt

Resp. 22 /mt

GENERAL PHYSICAL EXAMINATION

General Health fair

Oral hygiene good

Bones normal

Micturition normal

Sleep normal

PAST INVESTIGATION REPORTS

29/9/25 → Relatively defined, heterogeneously enhancing soft tissue density mass lesion arising from temporal aspect of vitreous chamber of (R) measuring 7.1 x 7.9 x 7.1 mm ± coarse calcifications ± focal thickening of (R) optic nerve.

9/10/25 CENTRE  
 ↳ poorly defined lobulated T1wt mildly hyperintense & T2wt hypointense lesion of 12x18x17 mm along lateral & post wall of globe of (R) orbit with mild post cont enhancement minimal extension of lesion to extraocular & intraorbital part of optic nerve & post contrast enhancement of length 11mm

20/12/25 → 11x9mm subtal enhancing focal lesion in PC of (R) globe associated with subretinal hemorrhage & enhancement of (R) optic nerve. No intracranial extension residual disease in sheath of (R) optic nerve.

30/10/25 PET scan - (No)

4/2/25 VH TRD in (R) globe ± an irregular nodular soft tissue (T2 hyper) lesion with cystic component noted in (L) lateral aspect of vitreous chamber measuring 8.5x11.8x5.6mm

mild enhancement of Perioptic nerve behind nerve head PLONE  
 No significant cont ON enhancement

DR. RAJENDRA PRASAD CENTRE FOR OPHTHALMIC SCIENCES  
 UHID: 108662073  
 CR No: R-01477426  
 Name: MISS. MAHIMA MAHIMA  
 Age: 35 MTD F  
 Date: 27/09/2026 10:50:25 AM  
 Ward Name: RPC 1B  
 -84293287 83  
 Unit In-charge: Dr. M. S. Bajaj  
 Unit: V  
 ACCOUNTS: 21-9234/202426 140  
 Bed No: 140

HTT :  
 FARRR FHO  
 FHTT

COMPLAINTS

- 1.
- 2.
- 3.
- 4.
- 5.

HISTORY

col  
 pvt


HISTORY

No

HISTORY

- Full T
- No M
- No D
- No

OTHER R



NCE

140

# ब० रो० वि० कार्ड O.P.D. Card



अनुभाग व दिन  
Section and Day  
मंगलवार व शुक्रवार  
Tuesday & Friday

कमरा नंबर  
Cabin No.

UJID: 108862073  
ABHA:  
Dept No: 20250050120

कमरा / Room: 32  
Unit-V  
OPD

Dr. Rechin Meel

TUE 13  
मंगल शुक्र

Registration time:  
13/02/2026 08:47:29 AM

आयु  
Age

पता  
Address

TRACHINA  
D/O AMARJEET YADAV  
M 3M 240 / F  
KANDARPUR BARIWA CHHAIANI  
TRACHINAGAR, UTTAR PRADESH  
PIN: 8419928783 General Rs 0  
Follow Up Patient

दिनांक DATE	निदान DIAGNOSIS	उपचार Treatment
13 Feb 2026	मिथिसा	<p>Ref'd to Dr Sameer Bhatnagar to plan enucleation after 6th chemo</p> <p>1/1/0 Persisting enhancement of OM till Chiasma</p>

Dr A (32A)  
after 3wks  
of next  
cycle

Need of  
Oppt.  
ICSF  
Rachna.

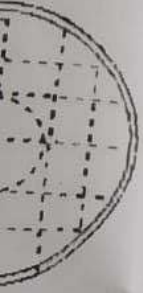
कृपया इस कार्ड को सुरक्षित रखें तथा अस्पताल में दिखाने के समय हर वक्त साथ लायें।

Kindly keep this Card safely and bring it on your follow-up visits.

- धूम्रपान निषेध 1. No Smoking
- कूड़ा कर्कट केवल कूड़ेदान में ही डालें 2. Use Dustbin
- थूकिये नहीं 3. No Spitting

shape  
ar  
er  
cularisation  
intact

D E F



Chauca

- PUPIL**
- Size
- Shape
- Position
- Synechia
- Reaction to direct light
- Consensual
- Accommodation
  
- LENS**
- Transparency
- Position
- Capsule
  
- VITREOUS**
- State
- Opacities
  
- INTRAOCULAR TENSION**
- Digital
- Instrumental, Schiotz
- Applanation
  
- BIOMICROSCOPIC FINDINGS (Digrams)**

**RIGHT**

**LEFT**

2mm → 4mm  
central  
circular  
D+

2mm → 6.5mm  
central  
circular.  
D+

clear


clear

~~clear~~  
Intravitreal mass ⊕

clear

Dig ⊕

Dig ⊕



BLOOMING LIVES FOUNDATION



# Histopathology Report

Ocular Pathology  
Dr. Rajendra Prasad Centre for Ophthalmic Sciences  
All India Institute of Medical Sciences  
Ansari Nagar, New Delhi - 110029, India

26-518

Name of the Patient: Mahima

Lab Reference No. : 26-546

Age : 2.5 Years      Sex : Female

Received on : 2/4/2026

UHID No. : 108662073

Date of Report : 7/4/2026

Ward IB      Bed No. : 140

Unit Incharge : Prof. Bajaj

Nature of the Material      Eucleation.  
Submitted :

Report :

- Eucleated right eye ball
  - Poorly differentiated retinoblastoma, right side (post chemotherapy) (LTD-15mm).
  - The tumor shows extensive calcification, subretinal fluid with retinal pigment laden macrophages and cholesterol clefts.
  - The iris, ciliary body and choroid are free of tumor.
  - The optic nerve shows extensive post laminar optic nerve infiltration.
  - The resected margin of the optic nerve is free of tumor.
- AJCC - ypT3b NoMo.

(Post chemo)

BLOOMING LIVES FOUNDATION

Reported By

Consultant : Dr. Seema Sen

ब. रो. वि. कार्ड  
O.P.D. Card

दृष्टि

अनुभाग व दिन  
Section and Day

V

कमरा नंबर  
Cabin No.

डा. राजेन्द्र प्र  
अ. भा. आयु.  
Dr. Rajendra P  
A.I.I.M.S., New  
यू.एच.आई.डी.  
UHID No.



UHID: 108662073  
ABHA:  
Dept No: 20250050120040

संख्या / Queue 25  
कमरा / Room: 32  
Unit-V  
RFC OPD

Dr. Rachna Meel

TUE, FRI  
मंगल, शुक्र



Registration time:  
10/04/2026 10:01:13 AM

MAHIM 1  
D/O AM. RJEET YADAV  
2Y 5M 21D / F  
CHANDARPUR BARWA CHHAWANI,  
KUSHINAGAR, UTTAR PRADESH,  
Mob: 8419028783 General Rs. 0  
Follow Up Patient

रोगी का  
Name of t

ता  
dress

दिनांक  
DATE

निदान  
DIAGNOSIS

(R) EORB III

उपचार Treatment

10 APR 2026

Post 6 cycle of chemo cycle.

Eucleated (R) globe

Shows ON extensive post lamellar.  
infiltration  
resected margin free of  
tumour

EUA date  
Smith  
ATK

Continue 6 more # of  
chemo.

RT registration Dr Sami IREH.  
(Thursday)

कृपया इस कार्ड को सुरक्षित रखें तथा अस्पताल में दिखाने के समय हर वक्त साथ लायें।

Kindly keep this Card safely and bring it on your follow-up visits.

1. धूम्रपान निषेध
2. कूड़ा कर्कट केवल कूड़ेदान में ही डालें
3. थूकिये नहीं
1. No Smoking
2. Use Dustbin
3. No Spitting

Routine / Emergency

Date 02/07/20 Anaesthesiologist

Dr. Seobli  
Dr. Rohan  
Dr. Divika  
Dr. Reshmita

Surgeon Dr. Meghna & team

Anaesth care start 1:15 PM

Anaesth. Care End

Induction Time 1:20

Surgery Start 1:25 PM

Surgery End 3:00 PM

Premedication

Induction (Inha / IV) O<sub>2</sub> + Sevo → Fentanyl 2µg + Propofol 15mg + Atropine 5mg

Maintenance: O<sub>2</sub> + Sevo + AFR

Airway device MASK/LMA/ETT proSeal LMA

Size # 1.5

Blade —

CL grade —

Attempts 1

Trauma —

Circuit —

Resp. Manual/Cont

Ventilatory mode VCV/PCV/SMU/PSU

Vt: 100ml F: 20/min

Insp. Press

A.W.P.

FIO<sub>2</sub> 0.5

Peak - 14 cmH<sub>2</sub>O

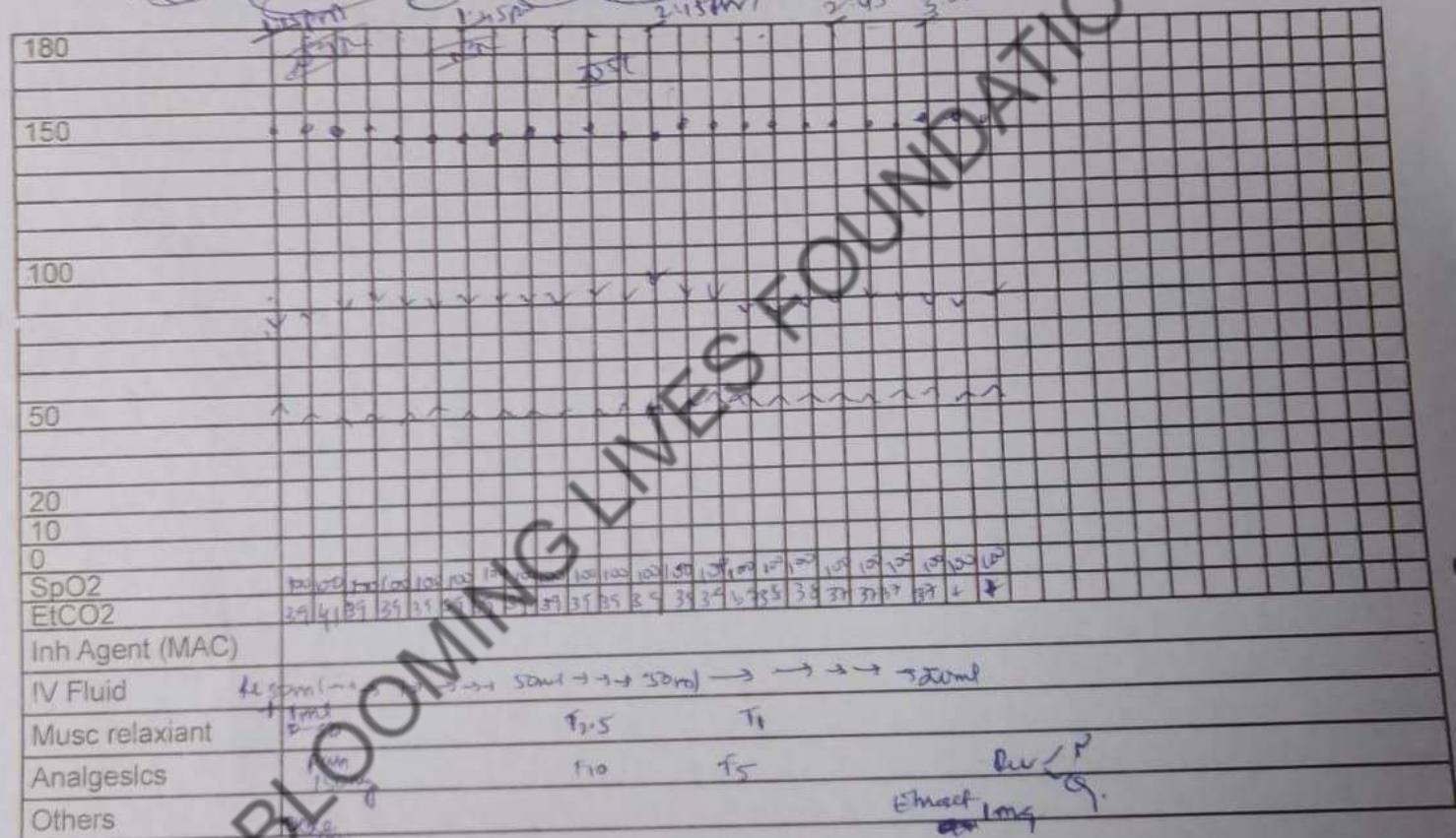
Regional block

Y/N

Drug

Vol

Monitoring ECG, Heart Rate, BP (M), SpO<sub>2</sub>, EtCO<sub>2</sub>, Temp. N.M. Monitoring, MAC, Agent conc



Blood Loss minimal Total Fluid 250ml Intra OP [Events if any]: VIE  
 Post OP Vitals: Consciousness ✓ Pulse 145/min SpO<sub>2</sub> 100% BP Nausea/Vomiting Pain (VAS)

Post OP Instruction: ✓ Left lateral position, ✓ O<sub>2</sub> by Mask, ✓ Watch for vitals, NPC till further Orders

Analgesia Bus. Paracetamol TDS Investigations

Inform SR anaesthesia on call SOS

Post OP Complications:

Signature Anaesthesiologist  
 Reshmita  
 DR - A

**Anaesthesia Record**  
**Dr. Rajendra Prasad Centre for Ophthalmic Sciences**  
**All India Institute of Medical Sciences, New Delhi-110029**

Name Pranima Age/Sex 2y/F Ward/Bed 140 HT/Wt 105kg CR.No. 014774-26 Ph. No. \_\_\_\_\_  
 ASA Grade 2 2 3 4 5 D E Diagnosis RE grape seg BART 40 Mo Mo W Surgery LE GVA + PC Eye

History-Prematurity/Post gestational age / cyanosis / aponea / drugs  
Primord / CIAS / no info given admission  
40 whitish opacity 6m ago 4th eyelet of CT REC  
(last on 2/2/20)

Previous Anaesthesia Exposure & problems if any :

Congenital Anomalies/Syndrome :

Airway examination : 1 piratni alm ay  
 Mallampati Class : 1 Teeth Neck movements Retrognathia Mouth Opening

High arched/cleft palate Tonsils Nasal Patency Facies Tongue

Intubation : simple/difficult

Respiratory System :

Resp. Rate Auscultation Blu Act Breath Holding Time (BHT) :

Cardiovascular System : Heart rate BP PR

Heart Sounds S2S2 (+) Adventitious mnds if any :

IV access : difficult

Nervous System : Delayed mile stones / Seizures / Mental retardation

Musculoskeletal system examination

Investigations

Hb 11.7 ESR TLC/DLC 12 B.Urea S. Cr Na/K 37/4.2 Ca

B. Sugar F. PP RBS LFT : Billirubin : T.P/A/G OT/PT TFT

X-Ray Chest ECG

ECHO

CT Brain MRI Other

Preanaesthetic Instructions : NPO Since

• Blu parental consent

• NPO < 8hr - solids  
> 2hr - clear fluids

Premedication

Drug Dose Route Time

Pranima  
**Signature Anaesthesiologist**

BLOOMING LIVES FOUNDATION

NPO x 10hr  
 Fluid :  
 M 90 40 40  
 P 200 200 100  
 T 240 140 140