

UHID: 10391409  
 Dept. No. 20240050034523  
 Clinic. No.: 2024/RB/77  
 ARPIT YADAV  
 S/O: AJAY YADAV

4Y/M

Date: 13/06/2024  
 General  
 Retinoblastoma-Dr. SR/JR  
 RETINOBLASTOMA  
 UNDER UNIT V R.142  
 Unit: V THU  
 Room No.: 142 B

अनुभाग व दिन  
 Section and Day  
 मंगलवार व शुक्रवार  
 Tuesday & Friday

कमरा नंबर  
 Cabin No.

Address: ALLAHABAD, UTTAR PRADESH, INDIA  
 Mobile: 8347403029



पू०ए०आ०२००३१० १००१

बजाज का एकक

UHID No.

Prof. M. S. Bajaj's Unit

रोगी का नाम Name of the Patient	पुत्र/पुत्री/पत्नी S/D/W	लिंग Sex	आयु Age	पता Address
------------------------------------	-----------------------------	-------------	------------	----------------

दिनांक DATE	निदान DIAGNOSIS
----------------	--------------------

उपचार Treatment

20/26  
 VA Cardif 1  
 6/19  
 (Asom)

(R) - EORB  
 (L) - WNL

No. of chemo cycle :- 03 (20/5/24)  
 EBRT/LAC - NONE  
 Last EVA done on 20/05/24

In - uncooperative

Cpt did not bring MRI films

To come on Wednesday (19/5/24)  
 (11 am) Room No.

कृपया इस कार्ड को सुरक्षित रखें तथा अस्पताल में दिखाने के समय हर वक्त साथ लायें।

Kindly keep this Card safely and bring it on your follow-up visits.

1. धूम्रपान निषेध 2. कूड़ा कर्कट केवल कूड़ेदान में ही डालें 3. थूकिये नहीं
1. No Smoking 2. Use Dustbin 3. No Spitting

53

डा० राजेन्द्र प्र  
अ० भा० आयु०

Dr. Rajendra P  
A.I.I.M.S., New

यू०एच०आई०डी०  
UHID No.

DR. B.R.A. IRCH/AIMS, NEW DELHI  
Reg. Date-27/03/2024  
Clinic No. 2024/121841  
Dept. MEDICAL ONCOLOGY  
Clinic Paed. Lymphoma Leukemia Clinic  
General  
Name ARPIT YADAV  
S/O- AJAY YADAV  
Phone No. 8347405029  
Address ALLAHABAD, UTTAR PRADESH, INDIA

कमरा नंबर  
Cabin No.

Prof. M. S. Bajaj's Unit

रोगी का नाम Name of the Patient	पुत्र/पुत्री/पत्नी S/D/W	लिंग Sex	आयु Age	पता Address
Arpit Yadav	CPE	M	40yrs	

दिनांक DATE	निदान DIAGNOSIS	उपचार Treatment
27/3/24	Stage III (R) ExtraOcular Rb of orbital man. and epi neu	Therapy till Area III C/S Dr. Rachna in Rb clinic

Refd to IRCH

- Dr. Sameer Bakhshi Mon/Thu →
- Dr. Saini Tues/Fri for EBRT Repitha

Mr. Sharminder

9315475107

Date for EUA & Swabs

Arpit

Kindly Accomodate  
Dharamshale

Archer

कृपया इस कार्ड को सुरक्षित रखें तथा अस्पताल में दिखाने के समय हर वक्त साथ लायें।

Kindly keep this Card safely and bring it on your follow-up visits.

1. धूम्रपान निषेध
2. कूड़ा कर्कट केवल कूड़ेदान में ही डालें
3. थूकिये नहीं

1. No Smoking

2. Use Dustbin

3. No Spitting

27/3/24

S7

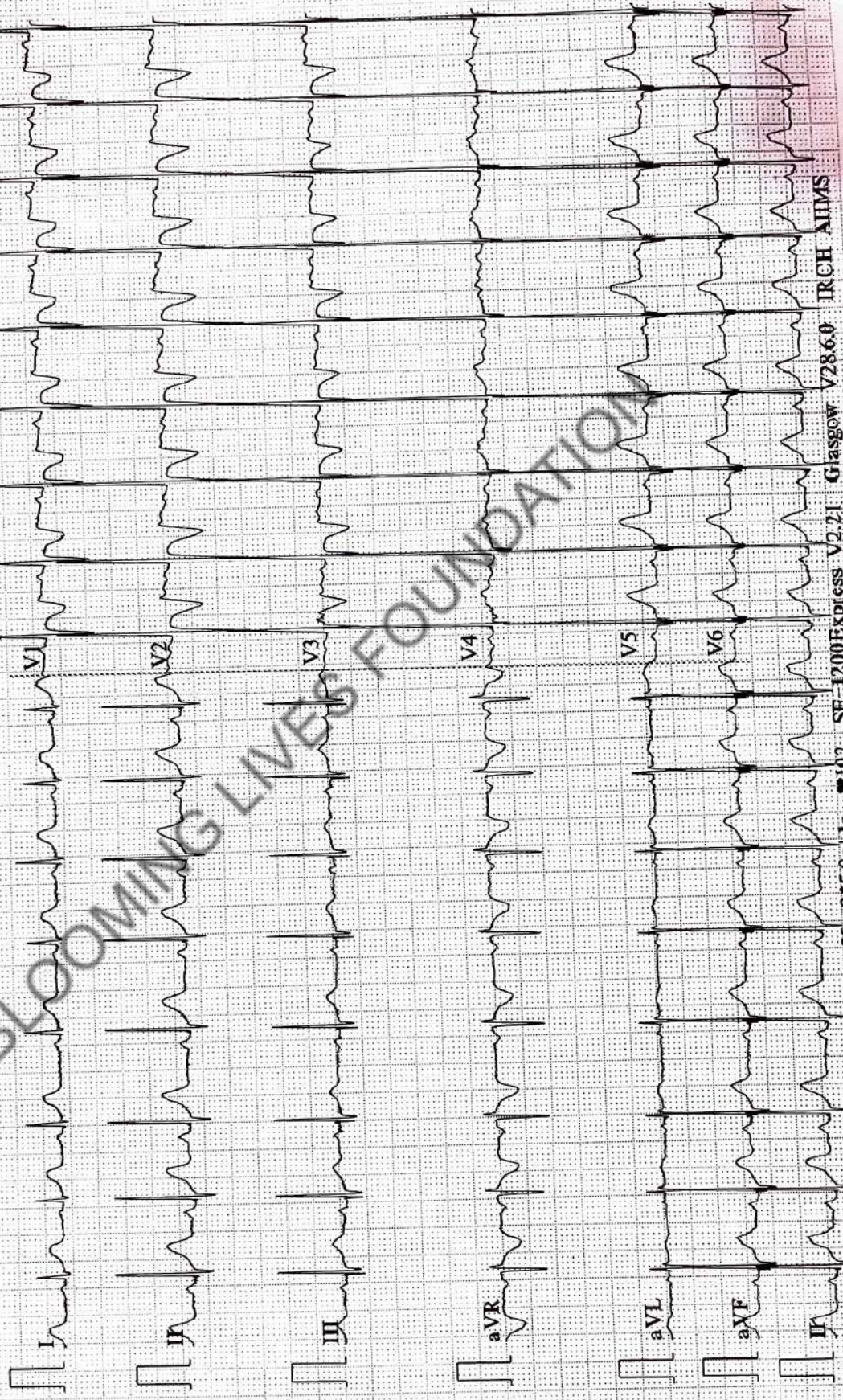
Arpit J. de

Male      Years

HR : 102 bpm  
 P : 86 ms  
 PR : 120 ms  
 QRS : 72 ms  
 QT/QTc : 314/409 ms  
 P/QRS/T : 64/66/52 °  
 RV5/SV1 : 3.056/0.812 mV

**Diagnosis Information:**  
 Sinus tachycardia with sinus arrhythmia  
 Right ventricular hypertrophy  
 Anterior T wave abnormality is nonspecific  
 Abnormal ECG

Report Confirmed by:



0.67~100Hz AC50 25mm/s 10mm/mV 2\*5.0s+1r

SE-1200Express V2.21 Glasgow V28.6.0 IRCH AIIMS

डॉ. राजेन्द्र प्रसाद नेत्र विज्ञान केन्द्र / Dr. Rajendra Prasad Centre for Ophthalmic Sciences

अखिल भारतीय आयुर्विज्ञान संस्थान/ALL INDIA INSTITUTE OF MEDICAL SCIENCES

एन.एम.आर. विभाग / DEPARTMENT OF N.M.R.

नैदानिक एम. आर.आई माँग प्रपत्र / CLINICAL MRI REQUISITION FORM

1. Clinical Dept. or Unit V Date of Requisition 19/03/2024
- OPD No. VHID-167391409 CR No. 167391409 Ward / Bed No.
2. Screening Dept. : Radio-diagnosis  Neuro-Radiology  Cardiac Radiology   
(Tick as appropriate)
3. रोगी का नाम /Patient's Name Anjit Yadav आयु /Age 47 लिंग /Sex M  
(साफ अक्षरों में / In Block letters)
- जन्म तिथि /Date of Birth : दिन /Day          माह /Month          वर्ष /Year          वजन /Weight          कि. ग्रा. /kg.
4. General Patient Condition (Tick as appropriate)  
(i) Critical and with life support (ii) Ill but without life support (iii) Ambulatory
5. Clinical Details : History :

Examinations:

Extra Ocular Rb.

Relevant Investigations :

Previous CT / MR / Other Reports / Studies

(with numbers, if any)

6. Clinical Diagnosis : CE MRI Orbit & Brain

7. Exact Anatomical site for MRI :

8. Special Instructions (Sedation, Allergy or other details which may facilitate a safe and informative study).

10. (a) Contrast Enhancement Required : Yes          No         

(b) Implant in Body (Tick as appropriate)

Cardiac Pacemaker          Aneurysmal clips          Cardiac Valve/Prosthesis          MEEL         Metallic Implants          Sharpnel/Pellet          Others          None          nology         हस्ताक्षर / Signature Anjit Yadav Associate Professor          nces          -29नाम / Name Anjit Yadav आ.आ.सं.         

(साफ अक्षरों में / In Block letters)

पदनाम / Designation         

(Requisition may be signed by a Faculty Member/Sr. Resident)

# Anaesthesia Record

Dr. Rajendra Prasad Centre for Ophthalmic Sciences  
All India Institute of Medical Sciences, New Delhi-110029

Name: Anupam Yadav      Age/Sex: 41M      UHID: 107391409      Ht/Wt: 18kg      CR.No.  
ASA Grade: 1 2 3 4 5 E      Diagnosis: FORB gyp E      Procedure: EVA      Mobile No.

Significant history/ medication:

FT

Prematurity: Yes/No

Post gestational age:

Cyanosis / apnoea:

Previous Anaesthesia Exposure & its complications:

Congenital Anomalies/Syndrome:

pediatric airway

Airway examination: Mouth opening:      Mallampati Class      Teeth      Tongue

Neck movements      Retrognathia      High arched/cleft palate      Tonsils

Intubation: simple / difficult

Respiratory System:      Resp. Rate      Auscultation B/L

Cardiovascular System:      Pulse rate/ Heart rate

Heart Sounds      Murmur NO murmur

Any Significant finding

Preop.SpO<sub>2</sub>

IV access: Easy / Difficult

Nervous System: MR / Delayed mile stones / CP / Seizures

Musculoskeletal system examination: head holding / difficulty in walking/ climbing stairs/ doing every day tasks

Investigations:      HB      RFT      LFT      TFT

X-Ray Chest      ECG      ECHO


CT Brain      MRI

**Anaesthesia details:**

SN	Date	Induction	Airway device	Anaesthesia maintenance	Procedure	Extubation	Anaesthesia team
	20/5/24	SevO. Inhalation	Classic CMA2-0	SevO 20 5000	FUA		Dr Sudarshan Dr Subhuti Dr Karanvi

PACU: O2 by face mask

Remarks:



Patient Name: MASTER ARPIT YADAV	Center Name: A S HEALTH SQUARE
Age / Sex: 4 Y / M	Referred By: AIIMS
Patient ID: 16207	Date: 20/03/2024

### CEMRI BRAIN WITH ORBIT

MR IMAGING OF BILATERAL ORBITAL REGION WAS PERFORMED ON A 1.5 T MR SYSTEM USING STIR, T1W AND T2W SECTIONS IN AXIAL AND CORONAL PLANES AND CORRELATED WITH T2W SAGITTAL OBLIQUE IMAGES. ADDITIONAL, AXIAL T2 & FLAIR IMAGES OF BRAIN WERE OBTAINED. POST GAD T1 WEIGHTED FS IMAGES WERE OBTAINED IN MULTIPLE PLANES.

#### ORBIT:

*The study reveals well defined lobulated right intraocular mass lesion in posterior segment arising from retina. The lesion is involving vitreous. No extraocular extension is seen. The lesion appears hyperintense on T1W images and hypointense on T2W images with respect to vitreous. Post gadolinium lesion shows intense homogeneous enhancement. The lesion measures TR (1.8) x AP (1.0) x CC (1.9) cm. There is thickening of sclera. There is associated subretinal hemorrhage.*

*There is extra-ocular extension involving preseptal soft tissue anteriorly & posteriorly into retrobulbar space involving right optic nerve over 1.5 cm.*

Left eyeball is normal. Left optic nerve shows normal signal intensity and contours.

Bilateral extra-ocular muscles, intraconal and extraconal spaces show normal MR morphology with no evidence of any obvious focal signal alteration or collection apparent at present on the available MR images.

Retro-ocular space and fat planes are preserved.

Optic chiasma appears normal in contours and signal intensity. Bilateral cavernous sinuses appear normal.

#### BRAIN:

The study reveals no significant focal lesion in the brain. The cerebral parenchyma shows normal signal characteristics. Myelination pattern of the brain is normal.

No evidence of restricted diffusion noted. The basal ganglia, thalami and internal capsules appear normal.

The mid-brain, pons and medulla appear normal. The cerebellum appears normal.

The ventricular system appears normal. The septum is in mid line. The sulci, fissures & basal cisterns appear normal.

The pituitary gland, optic chiasm and bilateral parasellar regions appear normal.

DR. BRA INSTITUTE ROTARY CANCER HOSPITAL HOSPITAL  
ALL INDIA INSTITUTE OF MEDICAL SCIENCES  
RAILWAY CONCESSION FORM

UHID 107391409

IRCH No. 316601

Concession Certificate

Outward Journey

Concession to Cancer/ Thalassemia /Heart(Only for heart Operation)/T.B./Lupas Valgaris / Non infectious Leprosy / Patient suffering from severe /Moderate form of Hemophilla/ AIDS/Sickle cell Anaemia/Aplastic Anaemia/ Ostomy patients\*\* to be used by Office-in-charge of the Hospital recognized by Health Department of Government of the concerned State Government.

To

The Station Master

Prayagraj Junction

This is to certify that Mr./ Mrs. /Ms. **Arpit Yadav** Whose particulars are furnished below, is a bonafide Concession to **CANCER** / Thalassemia/Heart/TB/Lupas valgaris/Non-infectious Leprosy Major / Patients suffering from severe/moderate form of Hemophilia/ Aids/Sickle cell Anaemia / Aplastic Anaemia/ Ostomy patients \*\* required to travel from (Station) **Prayagraj Junction** (Station) to **Delhi** (Station). The patient has secured on admission for treatment / is travelling for periodically checkup at **IRCH(AIIMS)** hospital.

Particulars of the Patients

Age 4 Years  
Sex Male + one Attendant  
Station From New Delhi  
Date: 20/8/2024

Signature

Officer-in-charge of the

Department of central Government/  
State Government (Name of the State)

Seal/Stamp of the Hospital/Institute

\*\* Strike out where not applicable.

+ Indicate name of the Hospital (recognized by Health Department of Central Government or State Government concerned)

Note:

1. The certificate is valid for three months from the date of issue except for cancer patients which is valid for one year.
2. No alteration in this form is permitted.
3. Certificate should be issued to patients only for the station serving his place of Residence to the station serving the recognized hospital



चि.स.स.ए. डॉ.भा.रा.अ.स.रो.के.अ  
MSSU, Dr. BRA, IRCH  
अ.भा.आ.सं., नई दिल्ली-110029  
AIIMS, New Delhi-110029

भारत आधिकारिक  
Officer Incharge  
डॉ. बी.आर.एस.रो.के.अ.  
Dr. B.R.A.I.R.C.H.  
अ.भा.आ.सं.स्थान/A.I.I.M.S.  
नई दिल्ली





अखिल भारतीय आयुर्विज्ञान संस्थान, नई दिल्ली  
 ALL INDIA INSTITUTE OF MEDICAL SCIENCES, NEW DELHI  
 NATIONAL CANCER INSTITUTE

UHID:	107391409	Name:	Mr Arpit Yadav
Age :	4 years 4 months 23 days	Sex :	Male
Reg Date :		Verification Time:	25/05/2024 02:39 am
Ward Name:		Lab Ref No:	772
Unit Name :	Unit-V	Unit Incharge :	M.S Bajaj
Department :	R. P. Centre (Eye Centre)	Sample Collection Date:	24/05/2024 10:20 am
Lab Name:	NCI CORE LAB	Lab Sub Centre:	
Report Generated Date:	25/05/2024 02:39 am	Dept / IRCH No:	2024005003452
Recommended By:	Dr. Neelam Pushkar	Sample Recieved Date:	24/05/2024 05:55 PM

Sample Details : S240524427

Report

Test Name	Result	Comment	Normal Range
Albumin	4.060 g/dL		• 3.2 - 4.8 g/dL 0Y - 100Y (M)
Gamma-Glutamyl Transferase	10		• < 73 U/L 0Y - 100Y (M)
Uric Acid	4.100 mg/dL		• 3.7 - 9.2 mg/dL 0Y - 100Y (M)
HIV 1/ 2 Ag/Ab Combo	<0.050 Index		• > 1 Index Reactive 0Y - 100Y (A) • < 1 Index Non-reactive 0Y - 100Y (A)
HBsAg	<b>0.570 Index</b>		• > 1 Index Reactive 0Y - 100Y (A) • < 1 Index Non-reactive 0Y - 100Y (A)
UREA	21 mg/dL		• < 50 mg/dL 0Y - 65Y (A)
CREATININE	<b>0.390 mg/dL</b>		• 0.7 - 1.3 mg/dL 0Y - 100Y (M)
CALCIUM	9.600 mg/dL		• 8.7 - 10.4 mg/dL 0Y - 100Y (A)
PHOSPHOROUS	<b>6.600 mg/dL</b>		• 2.4 - 5.1 mg/dL 0Y - 100Y (A)
SODIUM (NA )	142 mmol/L		• 132 - 146 mmol/L 0Y - 100Y (A)
POTASSIUM (K )	4.400 mmol/L		• 3.5 - 5.5 mmol/L 0Y - 100Y (A)
CHLORIDE(CL-)	106 mmol/L		• 99 - 109 mmol/L 0Y - 100Y (A)
TOTAL BILIRUBIN	<b>0.250 mg/dL</b>		• 0.3 - 1.2 mg/dL 0Y - 100Y (A)
DIRECT BILIRUBIN	0.090 mg/dL		• < 0.3 mg/dL 0Y - 100Y (A)
INDIRECT BILIRUBIN	0.16 mg/dL		• < 0.9 mg/dL 0Y - 100Y (A)
SGPT/ALT	23.040 U/L		• 10 - 49 U/L 0Y - 100Y (A)
SGOT/AST	<b>48.710 U/L</b>		• < 34 U/L 0Y - 100Y (A)
TOTAL PROTEIN	7.600 g/dL		• 5.7 - 8.2 g/dL 0Y - 100Y (A)
ALKALINE PHOSPHATASE	<b>224 I.U.</b>		• 46 - 116 U/L 0Y - 100Y (A)
GLOBULIN	3.54		• 2.5 - 3.4 g/dL 0Y - 100Y (A)
A/G Ratio	<b>1.14689 ratio</b>		• 1.2 - 2.2 ratio 0Y - 100Y (A)

(antibanti)

Rotary Cancer Hospital  
M.G. Hospital  
Oncology Department



OPD Regn No. 101391409

Sex	Age	Date of Birth
M	4y	BSA = 0.65 m <sup>2</sup>

Diagnosis: Extraocular RB Stage III

Referral/Date

Treatment

4/4/24

CHI VEC  
 INJ EMESET 2.5 mg IVP  
 INJ DEEA 2mg IVP  
 ↓  
 INJ VCR 1mg IVP  
 INJ ETOPOSIDE 100 mg / 500 ml 5D / 2hr  
 INJ VINCOPHYTOPHYLLIDE CARBOPLATIN 365 mg / 250 ml 5D / 1 hr.  
 SYP ZOFER 2mg / 5ml : 5ml BD x 3 DAYS  
 SYP DEEA 2mg / 5ml : 5ml OD x 3 DAYS  
 TAB LANZOL JUNIOR 15mg OD BBF x 3 DAYS  
 F/U 25/04/24 : CBC/RFT/LFT

DAYCARE (12/12/12)  
 MEDICAL ONCOLOGY AIIMS TRIAL  
 Date 08/04/24  
 Time 7:30 AM

New put ward  
 day care  
 2nd floor

TSF = 10.2 mm  
 TE = 105 cm  
 WT = 14.8 kg  
 MBL = 15.3  
 BMI = 13.4  
 BMI/A = -1.6  
 BMI - 1.56  
 Post CHEMO:

NPW day 00

(दो बार 3 दिन तक)  
 (एक बार 3 दिन तक)  
 एक बार 20 मिनट  
 पर 3 दिन तक

Bone scan  
 RT registration (Tue/Fri)  
 मंगलवार/बुधवार

Dr. SUSHANT CHIB  
 Senior Resident  
 Dept. of Medical Oncology  
 B.R.A. IRCH  
 New Delhi-110029  
 A.I.M.S  
 Anand Nagar, New Delhi-29

अंगदान-जीवन का बहुमूल्य उपहार / ORGAN DONATION - A GIFT OF LIFE  
 O.R.B.O.AIIMS, 26688360, 26593444, www.orbo.org Helpline-1060 (24 hrs. service)

हर से जाने वाले रोगियों के लिए धरमशाला की सुविधा उपलब्ध है / Dharamshala facility is available for outstation patients



अखिल भारतीय आयुर्विज्ञान संस्थान, नई दिल्ली  
All India Institute Of Medical Sciences, New Delhi

UID: 107391409 Sex: Male  
Patient Name: Mr Arpit Yadav Sample Received Date: 29-Apr-2024 18:04 PM  
Age: 4Y 4m Department: Medical Oncology  
Lab Name: Dept of Laboratory Medicine Lab Sub Centre: Smart Lab New OPD Block  
Reg Date: 29-Apr-2024 18:04 PM Sample Collection Date: 29-Apr-2024 14:44 PM  
Recommended By: Lab Reference No: 2413917864

Sample Details : L112904241797

Sample Type : Whole Blood

Report

HEMATOLOGY

Test Name	Result	UOM	Reference
Hb	10.30	g/dL	11.0 - 14.0
Hematocrit	33.80	%	34 - 40
RBC count	4.50	$10^6/\mu\text{L}$	4.0 - 5.2
WBC count	10.14	$10^3/\mu\text{L}$	5.0 - 15.0
Platelet count	524.00	$10^3/\mu\text{L}$	200 - 490
MCV	75.10	fL	75 - 87
MCH	22.90	pg	24 - 30
MCHC	30.50	g/dL	
RDW-CV	17.00	%	11.6 - 14
Neutro	41.20	%	30-60%
Lympho	50.50	%	29-65%
Eosino	0.90	%	1-4%
Mono	7.20	%	2-10%
Baso	0.20	%	0-1%
NRBC	0	%	
Neutro - Abs	4.18	$10^3/\mu\text{L}$	1.5-8.0
Lympho- Abs	5.12	$10^3/\mu\text{L}$	6.0-9.0
Eosino - Abs	0.09	$10^3/\mu\text{L}$	0.1 - 1.0
Mono - Abs	0.73	$10^3/\mu\text{L}$	0.2 - 1.0
Baso - Abs	0.02	$10^3/\mu\text{L}$	0.02 - 0.1

-----End of Report-----

Dr. Sudip Kumar Datta  
(Biochemistry & Immunoassay)

Dr. Tushar Sehgal  
(Hematology & Coagulation)

Dr. Suneeta Meena  
(Serology)

Dr. Devendra Kr. Verma (M.D.)  
Laboratory Medicine)  
29-Apr-2024 18:17

Attention: Please collect blood samples by puncturing the rubber cap of the vacutainers. Manual opening of caps and filling it must be avoided strictly. Lab reports are subjected to pre-analytical errors due to inappropriate patient preparation, phlebotomy practices, storage & handling. Please inform SMART Lab in case of any discrepancies with the expected results on the same day on Ext.no. 2526



**LABORATORY ONCOLOGY UNIT, Dr. B.R.A. IRCH, AIIMS, NEW DELHI  
& NCI-AIIMS, JHAJJAR**

*Dot Centre  
Gate - 3*

**Requisition Form For Investigations**

<p>Name: _____</p> <p>UHID: _____</p> <p>Age/Sex: _____</p> <p>OPD/Ward: _____</p> <p>Routine/Urgent: _____</p>	<ul style="list-style-type: none"> <li>• Clinical Diagnosis</li> <li>• Clinical Details:</li>   <li>• Payment Status:</li> <li style="padding-left: 20px;">Paying</li> <li style="padding-left: 20px;">EHS (No:)</li> <li style="padding-left: 20px;">Exempted by (Sign &amp; Stamp)</li> </ul>
---	---

Parameters	Parameters	Parameters	Parameters
CBC+DLC	Amylase	FSH	CSF Chloride
CBC+DLC+ Reticulocyte	Lipase	LH	CSF Glucose
PT	Magnesium	Estradiol	CSF Protein
INR	Cholesterol	Progesterone	Peritoneal or Pleural or Drain or Other Fluid: Albumin
APTT	Triglyceride	Cortisol	Peritoneal or Pleural or Drain or Other Fluid: Creatinine
TT	VLDL	Vitamin D	Peritoneal or Pleural or Drain or Other Fluid: Glucose
D Dimer	LDL	Testosterone	Peritoneal or Pleural or Drain or Other Fluid: LDH
Fibrinogen	HDL	Iron	Peritoneal or Pleural or Drain or Other Fluid: Lipase
Glucose B	IgG	Transferrin	Peritoneal or Pleural or Drain or Other Fluid: Total Protein
Glucose F	IgA	Ferritin	Peritoneal or Pleural or Drain or Other Fluid: Triglyceride
Glucose PP	IgM	TIBC	Peritoneal or Pleural or Drain or Other Fluid: Urea
GTT-50g Glucose	LDH	Vitamin B12	Peritoneal/Pleural/Drain/Other Fluid: Amylase
GTT-75g Glucose	CRP	Folate	Urine Protein
GTT- 100g Glucose	IL-6	Homocysteine	Urine Glucose
Urea	HCV	Troponin	Urine Urea
Creatinine	CHIV	CKNAC	Urine Creatinine
Uric Acid	HBsAg	CK MB	Urine Uric acid
Calcium	Anti HAV (Total)	AFP	<p><b>Requesting Doctor</b></p> <p>Name : _____</p> <p>Department : _____</p> <p>Sign : </p> <p>Seal : _____</p>
Phosphorus	Anti HAV (IgM)	CA125 (Rs.500/-)	
Sodium	HBc IgM	CA19.9	
Potassium	HBc Total	CEA	
Chloride	HBcAg	PSA	
Total Bilirubin	TSH	Free PSA	
Direct Bilirubin	FT3	β-HCG	
SGPT/ALT	FT4	HbA1c	
SGOT/AST	T3		
Total protein	T4		
Albumin	Prolactin		
Alkaline Phosphatase	PTH		
GGT	Procalcitonin (Rs.1350/-)		

Remarks: .....



*AS*



(DEPT. OF EMERGENCY MEDICINE)

UHID No:107391409

आपातकालीन नं. (Emergency No): 2024/030/0029930

दिनांक DATE: 01/04/2024

समय TIME: 01:46:02 PM

NON-MLC

नाम NAME: MR ARPIT Yadav

आयु AGE : 4 years 3 months

लिंग /SEX : M

S/O : AJAY YADAV

पता ADDRESS: मकान संख्या H.NO: ALLAHABAD

गली / मुहल्ला STREET/MOH:

शहर/प्रखंड CITY/BLOCK:

पिन PIN:

राज्य STATE: UTTAR PRADESH

दूरभाष सं. PHONE NO: 8347405029

मोबाइल MOBILE NO: 8347405029

स्थान Location: Paediatrics Emergency

द्वारा BROUGHT BY: Relative :

Criticality: Red / Yellow / Green

Triage: Responsive/ Unresponsive HR /min BP mmHg RR /min spO2 %  
Shifted to Paeds/ Main/ New Emergency

Presenting Complaints

*Med onco*

*(R) Extra ocular. Rhotholostoma =  
Optic nerve thickening (Stage III),  
Came = severe headache.*

Primary Assessment (ABCDE) : Assessment Pentagon

Airway	Circulation	Disability
Open & stable : Yes/No If No.....	HR <i>159</i> /min	GCS <i>15/15</i>
Breathing: <i>26</i> /min Efforts: Normal/Poor/increased	CFT <i>2</i> secs. BP <i>107/80</i> mmHg	Pupil size <i>3mm</i> /min <i>Bye</i> <i>RTL</i>
Auscultation: Air entry: Normal/poor/Differential	Peripheral pulse: Poor/Good	Pupillary Reactions.....
Added sounds: None/Stridor/Wheeze/Crackles	Central pulse: Poor/Good	Motor activity: Normal & Symmetrical/Asymmetrical/ Posturing/Flacidity/Seizure
SpO2 on Room air <i>98%</i>	Skin temp: Warm/cool	Blood Sugar.....mg/dl
<i>WT = 18kg</i>	Others <i>(R) eye proptosis.</i>	Exposure: Temp..... Colour: Normal/pallor/cyanosis /mottled Any other skin lesions.....

Diagnosis

*(R) GORB - Stage III = severe headache,  
likely due to infiltration by  
fungus.*

*Adm*

*Diy Paracetamol 150mg IV stat  
Diy Emeset 4mg IV stat  
Diy Trameld 10mg IV stat.*



अखिल भारतीय आयुर्विज्ञान संस्थान, नई दिल्ली  
All India Institute Of Medical Sciences, New Delhi

UHID: 107391409 Sex: Male  
Patient Name: Mr Arpit Yadav Sample Received Date: 16-Jul-2024 04:35 AM  
Age: 4Y 6m Department: Medical Oncology  
Lab Name: Dept of Laboratory Medicine Lab Sub Centre: Smart Lab New OPD Block  
Reg Date: 16-Jul-2024 04:01 AM Sample Collection Date: 15-Jul-2024 16:28 PM  
Recommended By: Lab Reference No: 2414291388

Sample Details : LC1507242660

Sample Type : Serum

Report

BIOCHEMISTRY

Test Name (Methodology)	Result	UOM	Reference
Urea (Urease/GLDH)	17	mg/dL	17 - 49
Creatinine (Jaffe compensated)	0.4	mg/dL	0.3 - 0.5
Uric Acid (enzymatic colorimetric)	3.6	mg/dL	3.4 - 7.0
Calcium (5-Nitro-5'-methyl-BAPTA)	9.6	mg/dL	8.8 - 10.8
Phosphate (molybdate UV)	5.3	mg/dL	2.5-4.5
Sodium (Ion Selective Electrodes)	136	mmol/L	135 - 145
Potassium (Ion Selective Electrodes)	4.6	mmol/L	3.5-5.1
Chloride (Ion Selective Electrodes)	100	mmol/L	98-107
Bilirubin (I) (Colorimetric diazo)	0.17	mg/dL	0 - 1
Bilirubin (D) (Diazo Gen.2 Jendrassik-Grof)	0.10	mg/dL	0 - 0.2
Bilirubin (I) (Calculated)	0.07	mg/dL	0 - 0.9
ALT (IFCC without pyridoxal phosphate)	11	U/L	0 - 26
AST (IFCC without pyridoxal phosphate)	32	U/L	<=40
ALP (IFCC)	259	U/L	142 - 335
Total protein (Biares)	8.1	g/dL	6.0 - 8.0
Albumin (BCG)	4.1	g/dL	3.8 - 5.4
Globulin (Calculated)	4.0	g/dL	3.0 - 3.7
A/G ratio (Calculated)	1.0		0.8-2.0
Total Amylase (IFCC)	60.00	U/L	28 - 100
Lipase (Enzymatic colorimetric assay)	17.20	U/L	13 - 60
CK (U.L. acc. to IFCC liquid)	140.00	U/L	39-308

Dr. Sudip Kumar Datta  
(Biochemistry & Immunoassay)

Dr. Tushar Sehgal  
(Hematology & Coagulation)

Dr. Suneeta Meena  
(Serology)

Dr Sudip Kumar Datta MD  
(Biochemistry)  
16-Jul-2024 04:55

IMMUNOASSAY

Test Name (Methodology)	Result	UOM	Reference
-------------------------	--------	-----	-----------

Generated On 16 Jul 2024 04:55:45 Lab 7431

(This is a computer generated report signature not required)

Page 1

Attention: Please collect blood samples by puncturing the rubber cap of the vacutainers. Manual opening of caps and filling it must be avoided strictly. Lab reports are subjected to pre-analytical errors due to inappropriate patient preparation, phlebotomy practices, storage and transport. Please inform SMART Lab in case of any discrepancies with the expected results on the same day on Ext.no. 2526



Dr. Rajendra Prasad Centre For Ophthalmic Sciences  
**ALL INDIA INSTITUTE OF MEDICAL SCIENCES (AIIMS), New Delhi, 110029**  
 Discharge Report  
 PROVISIONAL DISCHARGE CERTIFICATE

24-11-16  
 29/11/24

11  
 14/8/24  
 call date  
 16/8/24  
 11/11/24

UMID :	107391409	Cr No:	R-030049-24
Name:	Mr Arpit Yadav	Department:	R. P. Centre (Eye Centre)
Age/Sex:	4 years 6 mons 24 days / Male	Unit:	Unit-V
Ward Name:	1B	Bed No.:	138
Address:	ALLAHABAD, UTTAR PRADESH, INDIA	Drug Allergy, if any :- ( )	
Mobile No:	8347405029	107391409	
Date of Admission:	19/07/2024 11:56:21 AM		
Date of Discharge :	26/07/2024 09:02:00 AM		

ICD Code:	C69.2
ICD Description:	Malignant neoplasm Retina

Diagnosis	.RE GROUP E RB STAGE 3 A ( EXTRAOCCULAR ) LE WNL
-----------	---

1 Bed Room  
 12/8/24

Investigation	Systemic .NIL SI	Ocular	VA RE - DENIES PL LE - CARDIFF @ 50cm 6/15 IOP RE - DIG LOW LE - 14 mmhg
---------------	------------------	--------	---

Treatment/Operative Procedure	Surgeon .DR ANGKU Date 25/07/2024	Surgery	→ .RE ENUCLEATION WITH PRIMARY IMPLANT UNDER GA ON STUMP - 10mm SILICON IMPLANT - 20 mm → ANTERIOR CONJUNCTIVAL THICKENING NOTED SENT FOR HPE (E) EUA : WNL.
-------------------------------	--------------------------------------	---------	---

Condition at Discharge	Vision ENUCLEATED EYE Anterior Seg. ENUCLEATED EYE	IOP Posterior Seg.	ENUCLEATED EYE ENUCLEATED EYE
------------------------	---	-----------------------	----------------------------------

Advice During Discharge	Oral ATX AUGMENTIN (228MG/5ML) 5 ML TDS X 5 days DTP PCM (125MG/5ML) 6 ML SOS FOR PAIN SVP DIGENE 1 TSP OD BBF X 5 days Follow Up WITH DR ANGKU IN OPD 308 AT 9 AM ON 2/8/24	Topical (R) E BID MIFLOX TDS E/O OCCUPOL TDS	Position COLLECT HPE REPORT FROM 7TH FLOOR PATH DEPT ON FOLLOW UP
-------------------------	--	---	--

⇒ Syp Omnicort 7ml OD ABF x 5 days

2/8/24  
 383  
 9cm

AIIMS FREE GENERIC PHARMACY  
 (✓) MEDICINE RECEIVED  
 NAME: \_\_\_\_\_  
 DATE: 26/8/24  
 SIGN: \_\_\_\_\_

Prepared By: Dr. Anshu Rajam  
 Signature Of Senior Resident  
 ANSHU  
 SR.

Date & Time  
 26/8/24

Di. 24



## अखिल भारतीय आयुर्विज्ञान संस्थान, नई दिल्ली

UHID:	107391409	Name:	Mr Arpit Yadav
Age :	4 years 7 months 5 days	Sex :	Male
Reg Date :		Verification Time:	06/08/2024 05:56 pm
Ward Name:	1B	Lab Ref No:	1603
Unit Name :	Unit-I	Unit Incharge :	
Department :	Medical Oncology	Sample Collection Date:	06/08/2024 08:11 am
Lab Name:	NCI CORE LAB	Lab Sub Centre:	
Report Generated Date:	06/08/2024 05:56 pm	Dept / IRCH No:	316601
Recommended By:	Dr. Amlesh Seth	Sample Recieved Date:	06/08/2024 02:22 PM

## Sample Details : E060824043

## Report

Test Name	Result	Comment	Normal Range
Hemoglobin	10.100 g/dL		• 13 - 17 g/dL 0Y - 100Y (M)
Hematocrit	32.9199 %		• 40 - 50 % 0Y - 100Y (M)
RBC Count	3.670 10 <sup>12</sup> /μL		• 4.5 - 5.5 10 <sup>6</sup> /μL 0Y - 10 <sup>6</sup> Y (M)
WBC Count	12.870 10 <sup>9</sup> /μL		• 4 - 10 10 <sup>3</sup> /μL 0Y - 100Y (A)
Platelet Count	341 10 <sup>9</sup> /μL		• 150 - 400 10 <sup>3</sup> /μL 0Y - 10 <sup>6</sup> Y (A)
MCV	89.700 fL		• 83 - 101 fL 0Y - 100Y (A)
MCH	27.5204 pg		• 27 - 32 pg 0Y - 100Y (A)
MCHC	30.6805 g/dL		• 31.5 - 34.5 g/dL 0Y - 100Y (A)
RDW	22.400 %		• 11.6 - 15 % 0Y - 100Y (A)
Neutrophils	58.000 %		• 40 - 80 % 0Y - 100Y (A)
Lymphocytes	28.500 %		• 20 - 40 % 0Y - 100Y (A)
Eosinophils	0.900 %		• 0 - 7 % 0Y - 100Y (A)
Monocytes	7.000 %		• 3 - 11 % 0Y - 100Y (A)
Basophils	0.400 %		• 0 - 2 % 0Y - 100Y (A)
Neutrophils - Abs	7.4646 10 <sup>9</sup> /μL		• 2 - 7 10 <sup>3</sup> /μL 0Y - 100Y (A)
Lymphocytes - Abs	3.66795 10 <sup>9</sup> /μL		• 1 - 3 10 <sup>3</sup> /μL 0Y - 100Y (A)
Eosinophils - Abs	0.11583 10 <sup>9</sup> /μL		• 0.02 - 0.5 10 <sup>3</sup> /μL 0Y - 10 <sup>6</sup> Y (A)
Monocytes - Abs	0.9009 10 <sup>9</sup> /μL		• 0.2 - 1 10 <sup>3</sup> /μL 0Y - 100Y (A)
Basophils-Abs	0.05148 10 <sup>9</sup> /μL		• 0 - 0.1 10 <sup>3</sup> /μL 0Y - 100Y (A)

Overall Comment :

Authorised Signatory

(.)

Verified By  
( ritulabnci )



Triglyceride	72 mg/dL	<ul style="list-style-type: none"><li>• &lt; 150 Normal (mg/dl) 0Y - 100Y (A)</li><li>• 150 - 199 Borderline High (mg/dl) 0Y - 100Y (A)</li><li>• 200 - 499 High (mg/dl) 0Y - 100Y (A)</li><li>• &gt; 500 Very High (mg/dl) 0Y - 100Y (A)</li></ul>
VLDL	14.4 mg/dL	<ul style="list-style-type: none"><li>• 0 - 30 mg/dL 0Y - 100Y (A)</li></ul>
LDL	102.500 mg/dL	<ul style="list-style-type: none"><li>• &lt; 100 Optimal (mg/dl) 0Y - 100Y (A)</li><li>• 100 - 129 Near Optimal (mg/dl) 0Y - 100Y (A)</li><li>• 130 - 159 Border Line High (mg/dl) 0Y - 100Y (A)</li><li>• 160 - 189 High (mg/dl) 0Y - 100Y (A)</li><li>• &gt; 190 Very High (mg/dl) 0Y - 100Y (A)</li></ul>
HDL	47.700 mg/dL	<ul style="list-style-type: none"><li>• &lt; 40 Low (mg/dl) 0Y - 100Y (A)</li><li>• &gt; 60 High (mg/dl) 0Y - 100Y (A)</li></ul>
LDL/HDL RATIO	2.14885 ratio	<ul style="list-style-type: none"><li>• 1 - 3.4 0Y - 100Y (A)</li></ul>
GLOBULIN	3.3	<ul style="list-style-type: none"><li>• 2.5 - 3.4 g/dL 0Y - 100Y (A)</li></ul>
A/G Ratio	1.21212 ratio	<ul style="list-style-type: none"><li>• 1.2 - 2.2 ratio 0Y - 100Y (A)</li></ul>
Overall Comment :		

Authorised Signatory:  
(.)

Verified By:  
( ritulabnci )

BLOOMING LIVES FOUNDATION



DISCHARGE SLIP

Date:  
16-08-2024

Indoor RegNo.:0

UHID: IRCH  
No.:316601

Ward:DayCare

Consultant Name:DR. SAMEER  
BAKHSI

Patient Name:Arpit Yadav

Age:4 Sex:Male

Admission Date:8/16/2024 12:00:00  
AM

Chemo. Protocol:

Diagnosis: OTHERS

Cycle/Day: c6 d2

DRUGS ADMINISTERED

CHEMOTHERAPY/IMMUNOTHERAPY GIVEN

SNo.	Drug Name	Drug Other	Final Dose	Unit	Soln	Infusion
1		inj Etoposide	100mg	500 ml	5%D	2 hrs

Advice:

Re-appointment In:

On:

Prescribed Treatment



Dr. NIKHIL VASUDEVA  
 Senior Resident (DM)  
 Medical Oncology  
 Dr. Nikhil Vasudeva  
 B.R.A.I.R.C.H. AIIMS, New Delhi

BLOOMING LIVES FOUNDATION

डा० बी० आर० अम्बेडकर संस्थान रोटरी कैंसर अस्पताल  
DR. B. R. AMBEDKAR INSTITUTE ROTARY CANCER HOSPITAL

अखिल भारतीय आयुर्विज्ञान संस्थान

ALL INDIA INSTITUTE OF MEDICAL SCIENCES

20/6/24

रोगी का नाम

Name of the Patient

Aapit Patel

Clinic No. ....

I.R.C.H. No. ....

क्र० सं०  
Sl. No.

अपेक्षित मात्रा  
Qty. Reqd.

- 1.
2. 20g VP-16 100mg - 1 Mail
- 3.
- 4.
- 5.
- 6.

प्राप्त किया (रोगी के हस्ताक्षर)

Received (Signature of Patient)

चिकित्सा अधिकारी के हस्ताक्षर

Signature of the Medical Officer



Department of Nuclear Medicine and PET-CT  
All India Institute of Medical Sciences  
New Delhi, India

Patient Name: ARPIT YADAV		Age/Sex: 4Y/M
Study ID: MDP-50-20803-24	UHID: 107391409	Date: 29.05.2024

Indication: C/o EORB- post chemotherapy(last 27.05.2024)

$^{99m}\text{Tc}$  – MDP WHOLE BODY BONE SCAN

**Findings:**

- Normal radiotracer distribution noted throughout the skeleton.
- Physiological radiotracer uptake noted in the growth plates of skeleton.
- Bilateral kidneys are visualized.

**IMPRESSION:**

- No definite scan evidence of osteoblastic skeletal metastases in the present study.

(Bone scan has low sensitivity for purely lytic lesions)

*[Handwritten Signature]*  
Senior Resident

Consultant



DISCHARGE SLIP

Date:  
01-05-2024

Indoor RegNo.:0

UHID: IRCH  
No.:316601

Ward:DayCare

Consultant Name:DR. SAMEER  
BAKHSHI

Patient Name:Arpit Yadav

Age:4 Sex:Male

Admission Date:5/1/2024 12:00:00  
AM

Chemo. Protocol:

Diagnosis: OTHERS

RB

Cycle/Day: c2

DRUGS ADMINISTERED

PREMEDICATION GIVEN

Inj Ondansetron 2 mg  
Inj Dexamethasone 2 mg

CHEMOTHERAPY/IMMUNOTHERAPY GIVEN

SNo.	Drug Name	Drug Other	Final Dose	Unit	Soln	Infusion
1		inj carboplatin	365mg	250 ml	5%D	1 hr
2		inj etoposide	100mg	500 ml	5%D	2 hrs
3		inj vcr	1mg	-	-	IVP

Advice:

Re-appointment In:

Prescribed Treatment

On:

*AS*

Signature of Physician

Dr. Jagadeesh kumar  
Senior Resident  
Department of Medical Oncology  
AIIMS, New Delhi



**Dr. B. R. AMBEDKAR INSTITUTE ROTARY CANCER HOSPITAL**  
**ALL INDIA INSTITUTE OF MEDICAL SCIENCES NEW DELHI**  
**DAYCARE DRUGS ADMINISTERED**

Date:20-06-2024


**Indoor RegNo.:**0 **UHID:**107391409 **IRCH No.:**316601 **Ward:**DayCare  
**Patient Name:**Arpit Yadav **Age:**4 **Sex:**MALE **Consultant Name:**DR. CHETAN R

**Hb:**gms/dl **Platelets:/Cumm** **TLC:Cumm** **ANC:Cumm** **UREA:mg%**  
**Creatinine:mg%** **Bilirubin:mg%** **SGOT(AST):I.U.** **SGPT(AST):I.U.** **Alk Ph:I.U.**  
**Diagnosis:**RETINOBLASTOMA **Protocol:**VEC in /kg D1,D2 q 4 wkly **Cycle/Day:** c4  
**Height:cms** **Weight:kg** **BSA:m2**

## CHEMOTHERAPY/IMMUNOTHERAPY GIVEN

SNo.	Drug Name	Drug Other	Final Dose	Unit	Soln	Infusion
1	Inj Carboplatin		365mg	250 ml	5%D	1 hr
2	Inj Etoposide		100mg	500 ml	5%D	2 hrs
3	Inj Vincristine		1mg	-	-	IVP

Signature of Nurse


 Signature of Physician

BLOOMING LIVES FOUNDATION



अखिल भारतीय आयुर्विज्ञान संस्थान, नई दिल्ली  
ALL INDIA INSTITUTE OF MEDICAL SCIENCES, NEW DELHI  
NATIONAL CANCER INSTITUTE

UHID	107391409	Name:	Mr Arpit Yadav
Age :	4 years 5 months 12 days	Sex :	Male
Reg Date :		Verification Time:	13/06/2024 06:16 pm
Ward Name:		Lab Ref No:	740
Unit Name :	Unit-I	Unit Incharge :	
Department :	Medical Oncology	Sample Collection Date:	13/06/2024 10:08 am
Lab Name:	NCI CORE LAB	Lab Sub Centre:	
Report Generated Date:	13/06/2024 06:16 pm	Dept / IRCH No:	316601
Recommended By:	Mr. nitin .	Sample Recieved Date:	13/06/2024 04:39 PM

Sample Details : S130624213

Report

Test Name	Result	Comment	Normal Range
Albumin	3.990 g/dL		• 3.2 - 4.8 g/dL 0Y - 100Y (A)
Gamma-Glutamyl Transferase	3		• < 73 U/L 0Y - 100Y (M)
Uric Acid	4.300 mg/dL		• 3.7 - 9.2 mg/dL 0Y - 100Y (M)
HBsAg	<b>0.170 Index</b>		• > 1 Index Reactive 0Y - 100Y (A) • < 1 Index Non-reactive 0Y - 100Y (A)
UREA	13 mg/dL		• < 50 mg/dL 0Y - 65Y (A)
CREATININE	<b>0.350 mg/dL</b>		• 0.7 - 1.3 mg/dL 0Y - 100Y (M)
CALCIUM	9.000 mg/dL		• 8.7 - 10.4 mg/dL 0Y - 100Y (A)
PHOSPHOROUS	<b>6.300 mg/dL</b>		• 2.4 - 5.1 mg/dL 0Y - 100Y (A)
SODIUM (NA)	139 mmol/L		• 132 - 146 mmol/L 0Y - 100Y (A)
POTASSIUM (K)	3.600 mmol/L		• 3.5 - 5.5 mmol/L 0Y - 100Y (A)
CHLORIDE(CL-)	106 mmol/L		• 99 - 109 mmol/L 0Y - 100Y (A)
TOTAL BILIRUBIN	0.380 mg/dL		• 0.3 - 1.2 mg/dL 0Y - 100Y (A)
DIRECT BILIRUBIN	0.130 mg/dL		• < 0.3 mg/dL 0Y - 100Y (A)
INDIRECT BILIRUBIN	0.25 mg/dL		• < 0.9 mg/dL 0Y - 100Y (A)
SGPT/ALT	30.990 U/L		• 10 - 49 U/L 0Y - 100Y (A)
SGOT/AST	<b>46.470 U/L</b>		• < 34 U/L 0Y - 100Y (A)
TOTAL PROTEIN	7.200 g/dL		• 5.7 - 8.2 g/dL 0Y - 100Y (A)
ALKALINE PHOSPHATASE	<b>196 I.U.</b>		• 46 - 116 U/L 0Y - 100Y (A)
GLOBULIN	3.21		• 2.5 - 3.4 g/dL 0Y - 100Y (A)
A/G Ratio	1.24299 ratio		• 1.2 - 2.2 ratio 0Y - 100Y (A)
HCV IgG	0.240 Index		• <= 0.8 Non Reactive Index 0Y - 100Y (A) • >= 1 Reactive Index 0Y - 100Y (A)

BLOOMING LIVES FOUNDATION



DISCHARGE SLIP

Date:  
29-05-2024

Indoor RegNo.:0

UHID: IRCH  
No.:316601

Ward:DayCare

Consultant Name:DR. SAMEER  
BAKHSI

Patient Name:Arpit Yadav

Age:4 Sex:Male

Admission Date:5/29/2024 12:00:00  
AM

Chemo. Protocol:VEC in /kg D1,D2 q 4 wkly

Diagnosis: RETINOBLASTOMA

Cycle/Day:c3

DRUGS ADMINISTERED

PREMEDICATION GIVEN

Inj Ondansetron 2 mg

Inj Dexamethasone 2 mg

CHEMOTHERAPY/IMMUNOTHERAPY GIVEN

SNo.	Drug Name	Drug Other	Final Dose	Unit	Soln	Infusion
1	Inj Etoposide		100mg	500 ml	5%D	2 hrs
2	Inj Vincristine		1mg	-	-	IVP
3	Inj Carboplatin		365mg	250 ml	5%D	1 hr

Advice:

Re-appointment In:

On:

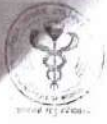Prescribed Treatment

*AM*

Signature of Physician

Dr. Jagadeesh kumar  
JAGADEESH KUMAR A  
Senior Resident  
Department of Medical Oncology  
New Delhi





अखिल भारतीय आयुर्विज्ञान संस्थान, नई दिल्ली  
All India Institute Of Medical Sciences, New Delhi

UHID: 107391409 Sex : Male  
Patient Name : Mr Arpit Yadav Sample Received Date : 29-Apr-2024 22:12 PM  
Age : 4Y 4m Department : Medical Oncology  
Lab Name: Dept of Laboratory Medicine Lab Sub Centre: Smart Lab New OPD Block  
Reg Date : 29-Apr-2024 19:44 PM Sample Collection Date: 29-Apr-2024 14:44 PM  
Recommended By: Lab Reference No: 2413918005

Sample Details : LG290424836-F

Sample Type : Plasma-Fasting

Report

BIOCHEMISTRY

Test Name	Result	UOM	Reference
Glucose F <small>(HENDON ISI)</small>	108.30	mg/dL	< 100

-----End of Report-----

Dr. Sudip Kumar Datta  
(Biochemistry & Immunoassay)

Dr. Tushar Sehgal  
(Hematology & Coagulation)

Dr. Suneeta Meena  
(Serology)

Dr Sudip Kumar Datta MD  
(Biochemistry)  
29-Apr-2024 22:55

BLOOMING LIVES FOUNDATION



अखिल भारतीय आयुर्विज्ञान संस्थान, नई दिल्ली  
All India Institute Of Medical Sciences, New Delhi

UHID: 107391409 Sex: Male  
Patient Name: Mr Arpit Yadav Sample Received Date: 04-Apr-2024 19:52 PM  
Age: 4Y 3m Department: Medical Oncology  
Lab Name: Dept of Laboratory Medicine Lab Sub Centre: Smart Lab New OPD Block  
Reg Date: 04-Apr-2024 18:11 PM Sample Collection Date: 04-Apr-2024 14:26 PM  
Recommended By: Dr. Praveen Aggarwal Lab Reference No: 2413807084

Sample Details : LG040424779-F Sample Type : Plasma-Fasting

Report

BIOCHEMISTRY

Test Name (Methodology)	Result	UOM	Reference
Glucose F (HPLC/KINASE)	85.50	mg/dL	< 100

-----End of Report-----

Dr. Sudip Kumar Datta  
(Biochemistry & Immunoassay)

Dr. Tushar Sehgal  
(Hematology & Coagulation)

Dr. Sunceta Meena  
(Serology)

Dr Sudip Kumar Datta MD  
(Biochemistry)  
04-Apr-2024 21:04

BLOOMING LIVES FOUNDATION

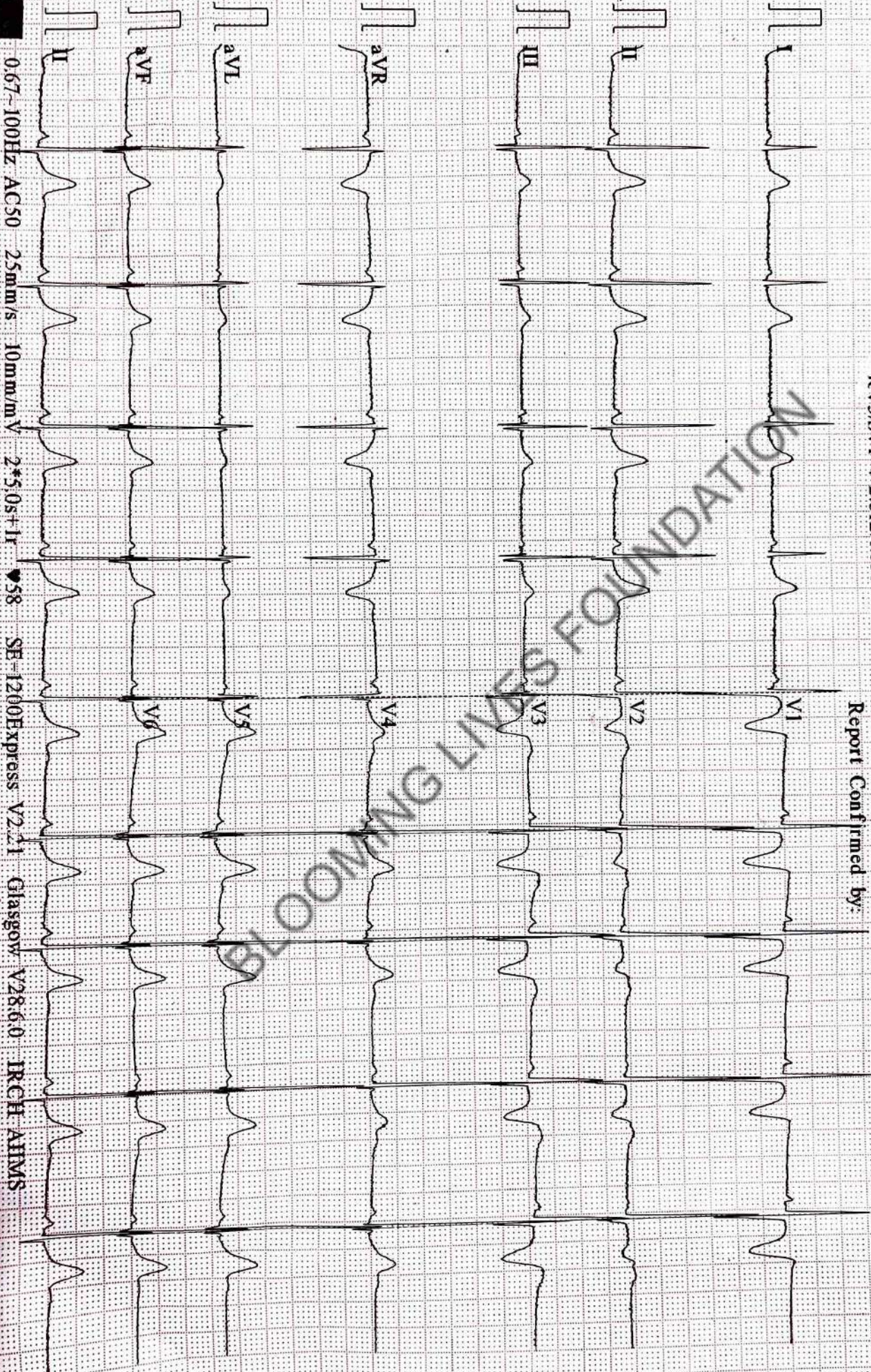
Male Years

*Arif + Madan*

HR : 58 bpm  
 P : 86 ms  
 PR : 114 ms  
 QRS : 70 ms  
 QT/QTc : 394/387 ms  
 P/QRS/T : 54/53/49 °  
 RV5/SV1 : 2.812/1.638 mV

Diagnosis Information:  
 \*\*\* ACUTE MI / ISCHEMIA \*\*\*  
 Sinus bradycardia with sinus arrhythmia  
 Anterior T wave abnormality suggests myocardial infarct  
 Abnormal ECG

Report Confirmed by:



14B PHDU

डा० राजेन्द्र प्रसाद नेत्र विज्ञान केन्द्र  
Dr. Rajendra Prasad Centre for Ophthalmic Sciences

एम.आर.-9  
M.R.-9

UHID:107391409	Date: 19/07/2024 11:56:21 AM
CR No.:R-030049-24	Ward Name: 1B
Name: MR ARPIT YADAV	Bed No: 138
Age: 4 Y 6 M 18 D/M	Unit In-charge: Dr. M. S. Bajaj
	Unit-V
S/O AJAY YADAV	ACCOUNTS-21-23311/202425 RS. 140
Address ALLAHABAD	UTTAR PRADESH

नई दिल्ली- 110029  
ncs, New Delhi-110029  
ATION RECORD

वैवाहिक स्थिति Marital Status	के.पं.सं. C.R. No.
व्यवसाय Occupation	धर्म Religion
	स्थिति Status

नाम  
Nan  
सेवा  
Ser

Referred by Dr. SR Dphthol  
Requesting Doctor

to Dr. SR PHDU  
Consultant & Specialty

Findings :

Date : 20/7/24

Respected man,  
clo (R) Extraorbital RB T side of HD/CT Pocket  
dominant for (R) nucleus & GA kindly evaluate if side dome  
for surgery. T two fornix over nasal  
retinal bank area.

Diagnosis or Impression :

Thank you  
20/07/24  
Dr. Mittal  
Dr.

20/7/2024

Thanks for Referral

Dr. Pooja HDU SR

Recommendations: clo (R) Extraorbital RB now T clo pustules @ bridge of  
nose & lateral contour of eye

O/E  
vitals stable  
Eys Exam - well

- Mupirocin ointment LABD
- Eyp. ANOXYCEAV (228mg/5ml) 5ml TDSx 5day
- local hygiene explained
- RV after 5 days

Consultant's Signature

Dr. Mittal

Patient Name: MASTER ARPIT YADAV	Center Name: A S HEALTH SQUARE
Age / Sex: 4 Y / M	Referred By: AIIMS
Patient ID: 34005	Date: 12/06/2024

## CEMRI BRAIN WITH ORBIT

MR IMAGING OF BILATERAL ORBITAL REGION WAS PERFORMED ON A 1.5 T MR SYSTEM USING STIR, T1W AND T2W SECTIONS IN AXIAL AND CORONAL PLANES AND CORRELATED WITH T2W SAGITTAL OBLIQUE IMAGES. ADDITIONAL, AXIAL T2 & FLAIR IMAGES OF BRAIN WERE OBTAINED. THE POST CONTRAST STUDY WAS PERFORMED AFTER I.V. INJECTION OF GADOLINIUM.

**Clinical profile: Follow up case of retinoblastoma.**

### ORBIT:

There is disorganization of right eyeball with altered signal intensity seen in posterior segment with area of vitreous hemorrhage with retinal detachment.

Right lacrimal gland is bulky with increased enhancement.

No residual enhancing mass is seen.

Left globe appears normal in MR morphology. No obvious vitreous hemorrhage and retinal detachment is seen. Bilateral optic nerves show normal signal intensity and contours.

Extra-ocular muscles, intraconal and extraconal spaces show normal MR morphology with no evidence of any obvious focal signal alteration or collection apparent at present on the available MR images.

Retro-ocular space and fat planes are preserved. Optic chiasma appears normal in contours and signal intensity.

### BRAIN:

Cerebral parenchyma show normal MR morphology with maintained grey-white matter differentiation. No focal lesion is seen. No midline shift seen. Corpus callosum is normal. No evidence of restricted diffusion noted.

The basal ganglia, thalami and internal capsules appear normal.

The mid-brain, pons and medulla appear normal. The cerebellum appears normal.

The ventricular system appears normal. The sulci, fissures & basal cisterns appear normal.

The pituitary gland and bilateral parasellar regions appear normal.

### IMPRESSION: MR findings reveal

- Disorganization of right eyeball with altered signal intensity in posterior segment with area of vitreous hemorrhage with retinal detachment.

Please correlate clinically.

Dr. SANDEEP DUA

HOD Radiology  
MBBS, MD

The above report is a professional opinion and needs to be correlated with clinical history and other relevant investigation for final diagnosis. If results are alarming or unexpected may be due to typographic errors, hence please contact within 7 days. (K)



भारत सरकार  
GOVT. OF INDIA  
वी.एम.एम.सी. एवं सफदरजंग अस्पताल, नई दिल्ली - 110029  
V.M.M.C. & SAFDARJUNG HOSPITAL, NEW DELHI-110029  
(दूरभाष Telephone : 011-26730000, 26165060)



UHID: 20240658788

CONSULTING ROOM NO : 1, TOKEN NO : 107  
Clinic Dental Clinic  
Days: MON, TUE, WED, THU, FRI, SAT

OUT PATIENT RECORD  
(Duplicate)

Name : MR. AJAY KUMAR

Department : Dental Surgery

Dept No. : 2024/080/0016860

Date of Registration : 05-06-2024 09:39:58 AM

Unit : 1

Age : 25Y

Billing Type : General

Mobile No : \*\*\*\*\*029

Address : , Prayagraj, UTTAR PRADESH, INDIA

Patient Type: NON MLC

Fee : 0.00

Sex : Male

S/O AMAR NATH

Email :

Occupation : OTHER

Prepared by: Mr. DEEPAKKR DEO DENTAL

C/O - Sensitivity to cold in the  
lower front region

M/H - N/A

H/O - Tobacco chewing

O/E - Gen Gingivitis  
Stains ++

Adv - Rx

Dessensitizing  
CHX Gluconate  
Tannic Acid

TIP<sup>oo</sup>  
M/W<sup>oo</sup>  
GIP<sup>oo</sup>

x mark

H

इंडव्लयूएस (आर्थिक रूप से कमजोर वर्ग) रोगियों के लिए महत्वपूर्ण सूचना

माननीय "उच्च न्यायालय दिल्ली" के अनुसार इंडव्लयूएस के व्यक्तियों जिनकी पारिवारिक आय 7254/- प्रतिमाह परिवार है, हेतु आमावाहनत निजी अस्पतालों द्वारा उपलब्ध करवाए जा रहे निःशुल्क उपचार का लाभ लेने के लिए संदर्भ सुविधा उपलब्ध है।

कृपया उपचार कर रहे चिकित्सक से संपर्क करें वे संदर्भ किए जाने के तंत्र की शुरुआत करेंगे।

अधिक जानकारी के लिए कृपया नोटिसबोर्ड देखें अथवा प्रभारी-ओपीडी (बाह्य रोगी मामलों में) यथ पंजीकरण काउंटर के पीछे, दूरभाष सं.

26707461 नोडल अधिकारी/सीएमओ-प्रभारी-कैज्युल्टी (भर्ती रोगियों के मामले में), कक्ष सं. 107 (भूतल), आपातकालीन ब्लॉक दूरभाष सं. 26707114



खाद्य तथा रसद विभाग

उत्तर प्रदेश शासन

जनपद : इलाहाबाद

पत्रांक क्रमांक

: 247520547695-217520631886

प्राप्त

: MANSATA

विभाग एवं शीतल

पुष्पिका का नाम

: श्रीमती श्रीमती

पिता / पति का नाम

: श्री बजरत्न

देवीकांति

: सिद्धेश्वर

पिता का पता

: 80, MANSATA, MANSATA, BARAON, एलाहाबाद - 211013.

आधार / पैनल नं. : XXXX XXXX 4564

पैसा यादृक क्रमांक नं. : — — —

पैन एड्रेसी का नाम

उत्पन्न दर कुकाव

मिनटों का विवरण

: साराण

: 5 ( FIVE )

दिनांक : 17-01-2016

Digitally Signed By  
RATAN KUMAR

Ratan Kumar / एलाहाबाद (राज्य)

राष्ट्रीय खाद्य सुरक्षा अधिनियम-२०१३ के अन्तर्गत डिजिटली हस्ताक्षरित पत्रांक है।  
IT Software Provided By: National Informatics Centre (NIC), UP. Date: 17-01-2016 09:00 PM

BLOOMING LIVES FOUNDATION

107391409

डॉ. राजेन्द्र प्रसाद नेत्र विज्ञान केन्द्र / Dr. Rajendra Prasad Centre for Ophthalmic Sciences  
अखिल भारतीय आयुर्विज्ञान संस्थान/ALL INDIA INSTITUTE OF MEDICAL SCIENCES

एन.एम.आर. विभाग / DEPARTMENT OF N.M.R.

नैदानिक एम. आर.आई माँग प्रपत्र / CLINICAL MRI REQUISITION FORM

1. Clinical Dept. or Unit Aspit yadav Date of Requisition 10/6/24  
OPD No. .... CR No. .... Ward / Bed No. ....

2. Screening Dept. : Radio-diagnosis  Neuro-Radiology  Cardiac Radiology   
(Tick as appropriate)

3. रोगी का नाम /Patient's Name ..... आयु / Age 4y लिंग /Sex M  
(साफ अक्षरों में / In Block letters)

जन्म तिथि /Date of Birth : दिन /Day ..... माह /Month ..... वर्ष /Year ..... वजन /Weight ..... कि. ग्रा. /kg.

4. General Patient Condition (Tick as appropriate)

(i) Critical and with life support (ii) Ill but without life support (iii) Ambulatory

5. Clinical Details : History :

Examinations:

RE EORB = orbital extension  
LE WNL

Relevant Investigations :

3 chemo cycles done

Previous CT / MR / Other Reports / Studies

(with numbers, if any)

6. Clinical Diagnosis : CE MRI Brain + orbit

7. Exact Anatomical site for MRI :

8. Special Instructions (Sedation, Allergy or other details which may facilitate a safe and informative study).

(a) Contrast Enhancement Required : Yes ..... No .....

(b) Implant in Body (Tick as appropriate)

Cardiac Pacemaker ..... Aneurysmal clips ..... Cardiac Valve/Prosthesis .....

Metallic Implants 10/12/24 ..... Sharpnel/Pellet ..... Others ..... None .....

DATE 10/12/24  
OT: .....  
NPR: .....  
RPT: .....  
WTR: .....  
PAYMENT: .....  
SIGN h.s. RB

ICM  
prc

हस्ताक्षर / Signature .....

नाम / Name .....

(साफ अक्षरों में / In Block letters)

पदनाम / Designation .....

(Requisition may be signed by a Faculty Member/Sr. Resident)





अखिल भारतीय आयुर्विज्ञान संस्थान, नई दिल्ली  
All India Institute Of Medical Sciences, New Delhi

UHID: 107391409 Sex : Male  
Patient Name : Mr Arpit Yadav Sample Received Date : 04-Apr-2024 22:30 PM  
Age : 4Y 3m Department : Medical Oncology  
Lab Name: Dept of Laboratory Medicine Lab Sub Centre: Smart Lab New OPD Block  
Reg Date : 04-Apr-2024 16:30 PM Sample Collection Date: 04-Apr-2024 14:26 PM  
Recommended By: Dr. Praveen Aggarwal Lab Reference No: 2413806918

Sample Details : LC0404242135

Sample Type : Serum

Report

IMMUNOASSAY

Test Name (Methodology)	Result	UOM	Reference
Dr. Sudip Kumar Datta (Biochemistry & Immunoassay)	Dr. Tushar Sehgal (Hematology & Coagulation)	Dr. Suneeta Meena (Serology)	Dr Arkadipta Mukherjee 05-Apr-2024 02:40

BLOOMING LIVES FOUNDATION

04/05/2024 02:41:24 12113388

This is a computer generated report and no signature is required.

**Attention:** Please collect blood samples by puncturing the rubber cap of the vacutainers. Manual opening of caps and filling it must be avoided strictly. Lab reports are subjected to pre-analytical errors due to inappropriate patient preparation, phlebotomy practices, storage and transport. Please inform SMART Lab in case of any discrepancies with the expected results on the same day on Ext.no. 2526



**ALL INDIA INSTITUTE OF MEDICAL SCIENCES  
(AIIMS)  
New Delhi**



UHID: 107391409 Reg Date: 19/03/2024 08:55 AM  
Patient Name: Mr Arpit Yadav Age: 4 years 2 months 27 days  
Sex: Male Department: Medical Oncology  
Unit Name: Unit-I Unit Incharge:  
SRF ID:

Sample Details: LOI-280324102-CS (CSF) Collection Date :28/03/2024 11:33 AM

Report Generated on: 08/04/2024 08:39 AM

**CSF For Morphology**

C-695/24.

CSF cytopspin smear show few lymphomononuclear cells and few degenerated cells.

Senior Resident : Dr Vanlalhruii

Consultant: Dr Amar Ranjan

REMARKS:-

Sample Details : LOI-280324103-BP (Bone Marrow) Collection Date :28/03/2024 11:33 AM

**BMA BMT PS**

Report: Cellular bone marrow preparation shows haematopoietic cells of all series series (M:E=4.8:1) along with 2% blasts.

There is no evidence of infiltration/ metastasis in the smears examined.

Peripheral smear is unremarkable.

Kindly correlate with bone marrow biopsy

Senior Resident : Dr Vanlalhruii

Consultant: Dr Amar Ranjan

**This is an electronically generated report, authorized signature is not required. The test reports have been authenticated. Partial reproduction of the report is not permitted.**

**Authorized Signatory**



अखिल भारतीय आयुर्विज्ञान संस्थान, नई दिल्ली  
All India Institute Of Medical Sciences, New Delhi

UHID: 107391409 Sex : Male  
Patient Name : Mr Arpit Yadav Sample Received Date : 04-Apr-2024 16:30 PM  
Age : 4Y 3m Department : Medical Oncology  
Lab Name: Dept of Laboratory Medicine Lab Sub Centre: Smart Lab New OPD Block  
Reg Date : 04-Apr-2024 16:30 PM Sample Collection Date: 04-Apr-2024 14:25 PM  
Recommended By: Dr. Praveen Aggarwal Lab Reference No: 2413806917

Sample Details : LH0404241496

Sample Type : Whole Blood

Report

HEMATOLOGY

Test Name (Methodology)	Result	UOM	Reference
Hb (NTS) (ometry)	11.80	g/dL	11.0 - 14.0
Hematocrit (Direct Measure)	39.50	%	34 - 40
RBC count (Impedance)	5.33	10 <sup>6</sup> /μL	4.0 - 5.2
WBC count (Flow cytometry)	12.50	10 <sup>3</sup> /μl	5.0 - 15.0
Platelet count (Impedance)	897.00	10 <sup>3</sup> /μL	200 - 490
MCV (Calculated)	74.10	fL	75 - 87
MCH (Calculated)	22.10	pg	24 - 30
MCHC (Calculated)	29.90	g/dL	
RDW-CV (Calculated)	16.30	%	11.6 - 14
Neutro (Flow cytometry)	39.30	%	30-60%
Lympho (Flow cytometry)	45.90	%	29-65%
Eosino (Flow cytometry)	5.50	%	1-4%
Mono (Flow cytometry)	8.70	%	2-10%
Baso (Flow cytometry)	0.60	%	0-1%
NRBC	0	%	
Neutro - Abs (Calculated)	4.91	10 <sup>3</sup> /μl	1.5-8.0
Lympho- Abs (Calculated)	5.74	10 <sup>3</sup> /μl	6.0-9.0
Eosino - Abs (Calculated)	0.69	10 <sup>3</sup> /μl	0.1 - 1.0
Mono - Abs (Calculated)	1.09	10 <sup>3</sup> /μl	0.2 - 1.0
Baso - Abs (Calculated)	0.07	10 <sup>3</sup> /μl	0.02 - 0.1

Remarks: Microcytic Hypochromic Anemia. Advice- 1. Reticulocyte count 2. Iron studies 3. Hb HPLC (if clinically indicated, as per results of iron studies) 4. Kindly correlate clinically, Thrombocytosis present. Kindly rule out secondary causes of thrombocytosis.

-----End of Report-----

Dr. Sudip Kumar Datta  
(Biochemistry & Immunoassay)

Dr. Tushar Sehgal  
(Hematology & Coagulation)

Dr. Suneeta Meena  
(Serology)

Dr Tushar Sehgal DM  
(Hematopathology)  
04-Apr-2024 17:48

Attention: Please collect blood samples by puncturing the rubber cap of the vacutainers. Manual opening of caps and filling it must be avoided strictly. Lab reports are subjected to pre-analytical errors due to inappropriate patient preparation, phlebotomy practices, storage and transport. Please inform SMART Lab in case of any discrepancies with the expected results on the same day on Ext.no. 2526

# RADIO ISOTOPE INVESTIGATION REQUISITION FORM

DR. B.R.A. IRCH, AIIMS, NEW DELHI

IRCH No. 316601  
 Clinic Paed. Lymphoma Leukemia Clinic  
 Deptt. MEDICAL ONCOLOGY  
 General  
 नाम  
 Name ARPIT YADAV  
 S/O- AJAY YADAV  
 Phone No. 8347405029  
 Address ALLAHABAD, UTTAR PRADESH, INDIA

Reg. Date-27/03/2024

Clinic No. 2024/21841



UHID-107391409

Sex/Age M/4Y

Room 13 (Shift Morning)

TEL : 26588500/ EXT. 3210

Old RAK OPD

रोग

आयु / लिंग Age / Sex :

Referred by :

पंजीकरण सं० / Regd. No. :

**Examination Required :**

- Liver Scan
- Hepatobiliary Study
- Study for Duodeno gastric reflux
- Study for G.I Bleeding
  - \* Tc-O<sub>4</sub> abdominal scan
  - \* Blood Pool scan
- Gastro - esophageal Reflux
- Gastric Emptying Study
- Bone Scan
- Bone Marrow Scan
- Renal dynamic scan
- DMSA/GHA Renal scan
- DRCG/UFMT
- Renal Transplant Evaluation
- Renal clearance study
  - G.F.R.
  - E.R.P.F.
- Brain Spect scan
- MISCELLANEOUS (Only after discussion)
- Thyroid Scan
- R.A.I.U
- Perchlorate discharge Test
- T-4 Suppression Test
- I-131 whole Body Scan for Ca Thyroid
- R.B.C. Mass estimation
- Cr - 51 RBC survival study
- Gallium Scan
- Strontium Therapy
- MiBG Scan

**IMPORTANT**

L.M.P. :  
 S Cr :  
 Blood Urea :  
 Serum Bilirubin :  
 Haemoglobin :  
 P.C.V. :  
 PREVIOUS STUDY

5/6/24  
 92

**BRIEF CLINICAL HISTORY**

Extraocular Rb.  
 Baseline staging scan  
Bone scan

Sushant

Date

डॉ. सुशान्त चिब / Dr. SUSHANT CHIB  
 वरिष्ठ रेजिडेंट / Senior Resident  
 चिकित्सा अणुदिविज्ञान विभाग / Dept. of Medical Oncology  
 डॉ. भीराज सराठी की सर अस्पताल Dr. B.R.A. IRCH  
 Dr. BRAIRCH, (AIIMS), New Delhi-110029  
 अखिल भारतीय आयुर्विज्ञान संस्थान, ए.आई.एम.एस.  
 अंसारी नगर, नई दिल्ली - 110029  
 Referring Physician / Surgeon

Date:  
14-08-2024

DISCHARGE SLIP

Indoor RegNo.:0

UHID: IRCH  
No.:316601

Ward:DayCare

Consultant Name:DR. SAMEER  
BAKHSHI

Patient Name:Arpit Yadav

Age:4 Sex:Male

Admission Date:8/14/2024 12:00:00  
AM

Chemo. Protocol:

Diagnosis: OTHERS

Cycle/Day: c6

DRUGS ADMINISTERED

CHEMOTHERAPY/IMMUNOTHERAPY GIVEN

SNo.	Drug Name	Drug Other	Final Dose	Unit	Soln	Infusion
1		inj vcr	1mg		-	IVP
2		inj Carboplatin	370mg	500 ml	5%D	1 hr
3		inj Etoposide	100mg	500 ml	5%D	1 hr

Advice:

Re-appointment In:

On:

Prescribed Treatraent

BLOOMING LIVES FOUNDATION



Dr. NIKHIL VASUDEVA  
Senior Resident (DM)  
Medical Oncology  
Signature of Physician  
B.R.A.I.R.C.H. AIIMS,  
New Delhi  
Dr. Nikhil Vasudeva



अखिल भारतीय आयुर्विज्ञान संस्थान, नई दिल्ली

UHID:	107391409	Name:	Mr Arpit Yadav
Age :	4 years 5 months 12 days	Sex :	Male
Reg Date :		Verification Time:	13/06/2024 07:39 pm
Ward Name:		Lab Ref No:	1744
Unit Name :	Unit-I	Unit Incharge :	
Department :	Medical Oncology	Sample Collection Date:	13/06/2024 10:07 am
Lab Name:	NCI CORE LAB	Lab Sub Centre:	
Report Generated Date:	13/06/2024 07:39 pm	Dept / IRCH No:	316601
Recommended By:	Mr. nitin .	Sample Recieved Date:	13/06/2024 04:47 PM

Sample Details : E130624209

Report

Test Name	Result	Comment	Normal Range
Hemoglobin	9.300 g/dL		• 13 - 17 g/dL 0Y - 100Y (M)
Hematocrit	32.625 %		• 40 - 50 % 0Y - 100Y (M)
RBC Count	3.750 10 <sup>15</sup> /μL		• 4.5 - 5.5 10 <sup>15</sup> /μL 0Y - 100Y (M)
WBC Count	3.790 10 <sup>9</sup> /μL		• 4 - 10 10 <sup>9</sup> /μL 0Y - 100Y (A)
Platelet Count	197 10 <sup>9</sup> /μL		• 150 - 400 10 <sup>9</sup> /μL 0Y - 100Y (A)
MCV	87.000 fL		• 83 - 101 fL 0Y - 100Y (A)
MCH	24.8 pg		• 27 - 32 pg 0Y - 100Y (A)
MCHC	28.5057 g/dL		• 31.5 - 34.5 g/dL 0Y - 100Y (A)
RDW	23.100 %		• 11.6 - 15 % 0Y - 100Y (A)
Neutrophils	9.300 %		• 40 - 80 % 0Y - 100Y (A)
Lymphocytes	62.900 %		• 20 - 40 % 0Y - 100Y (A)
Eosinophils	1.800 %		• 0 - 7 % 0Y - 100Y (A)
Monocytes	12.400 %		• 3 - 11 % 0Y - 100Y (A)
Basophils	0.900 %		• 0 - 2 % 0Y - 100Y (A)
Neutrophils - Abs	0.35247 10 <sup>9</sup> /μL		• 2 - 7 10 <sup>9</sup> /μL 0Y - 100Y (A)
Lymphocytes - Abs	2.38391 10 <sup>9</sup> /μL		• 1 - 3 10 <sup>9</sup> /μL 0Y - 100Y (A)
Eosinophils - Abs	0.06822 10 <sup>9</sup> /μL		• 0.02 - 0.5 10 <sup>9</sup> /μL 0Y - 100Y (A)
Monocytes - Abs	0.46996 10 <sup>9</sup> /μL		• 0.2 - 1 10 <sup>9</sup> /μL 0Y - 100Y (A)
Basophils - Abs	0.03411 10 <sup>9</sup> /μL		• 0 - 0.1 10 <sup>9</sup> /μL 0Y - 100Y (A)

Overall Comment :

Authorised Signatory

( )

Verified By  
( anjulabnci )

Address ALLAHABAD, UTTAR PRADESH, INDIA  
 Phone No. 8347405029  
 S/O- AJAY YADAV  
 Name ARPIT YADAV  
 Reg. No. 316601  
 Dept. MEDICAL ONCOLOGY  
 Clinic Paed. Lymphoma Leukemia Clinic  
 IRCH No. 2024/121841  
 Reg. Date-27/03/2024  
 UHID-107391409

कमरा नंबर  
 Cabin No.

डा० राजेन्द्र प्र  
 अ० भा० आयु०  
 Dr. Rajendra P  
 A.I.I.M.S., New  
 यू.एच.आई.डी.  
 UHID No.

Prof. M. S. Bajaj's Unit

रोगी का नाम Name of the Patient	पुत्र/पुत्री/पत्नी S/D/W	लिंग Sex	आयु Age	पता Address
Arpit Yadav	S/D/W	M	4y	

दिनांक DATE	निदान DIAGNOSIS	उपचार Treatment
27/3/24	(R) ExtraOcular Rb & orbital man. and Stape III ephi neu	Flucloring till Area (III) Ref to Dr. Pachna in R&L clinic

Refd to IRCH  
 - Dr Sameer Bakshi Mon/Thu  
 - Dr Saini Tues/Fri for EBRT Registration

Mr. Sharminder  
 9315475107

Date for EUA & Swabs  
 Acharya

Kindly Accomodate  
 Dharamshala  
 Acharya


कृपया इस कार्ड को सुरक्षित रखें तथा अस्पताल में दिखाने के समय हर वक्त साथ लायें।  
 Kindly keep this Card safely and bring it on your follow-up visits

- धूम्रपान निषेध 1. No Smoking
- कूड़ा कर्कट केवल कूड़ेदान में ही डालें 2. Use Dustbin
- थूकिये नहीं 3. No Spitting

27/3/24

57

DR. RAJENDRA PRASAD CENTRE FOR OPHTHALMIC SCIENCES

PHID:107391409	Date: 20/05/2024 09:26:21 AM	
CR No: R-022112-24	Ward Name: RPC OT	Bed No: Temporary Bed
MR ARPIT YADAV	Unit In-charge: Dr. M. S. Bajaj	Unit-V
20/05/2024	ACCOUNTS-21-12416/202425	RS. 60
YADAV	UTTAR PRADESH	
LAHABAD		

अनुभाग व दिन Section and Day मंगलवार व शुक्रवार Tuesday & Friday	V
कमरा नंबर Cabin No.	

डॉ. बजाज का एकक  
 Dr. Bajaj's Unit

रोगी का नाम Name of the Patient	पुत्र/पुत्री/पत्नी S/D/W	लिंग Sex	आयु Age	पता Address
Arpit Yadav		M	44	

दिनांक DATE	निदान DIAGNOSIS
----------------	--------------------

उपचार Treatment

20/5/24

**RB - EUA**  
 - EUA done by Dr. Angan  
 Diagnosis : RE EORB . E orbital extension  
 LE WNL  
 Date of Enucleation (-)  
 HRF +/-  
 - No. of Chemo Cycles 2  
 - Last Chemo on 11/5/24  
 - EBRT /IAC/ Intravitreal (-)  
 - Last EUA (-)  
 RTI (-)

कृपया इस कार्ड को सुरक्षित रखें तथा अस्पताल में दिखाने के समय हर वक्त साथ लायें।  
 Kindly keep this Card safely and bring it on your follow-up visits.

1. धूम्रपान निषेध 1. No Smoking
2. कूड़ा कर्कट केवल कूड़ेदान में ही डालें 2. Use Dustbin
3. थूकिये नहीं 3. No Spitting





Dr. Rajendra Prasad Centre For Ophthalmic Sciences  
ALL INDIA INSTITUTE OF MEDICAL SCIENCES (AIIMS), New Delhi, 110029

Discharge Report  
PROVISIONAL DISCHARGE CERTIFICATE

24-11-16  
29/7/24

UHID :	107391409	Cr No:	R-030049-24
Name:	Mr Arpit Yadav	Department:	R. P. Centre (Eye Centre)
Age/Sex:	4 years 6 mons 24 days / Male	Unit:	Unit-V
Ward Name:	1B	Bed No.:	138
Address:	ALLAHABAD, UTTAR PRADESH, INDIA	Drug Allergy, if any :- []	
Mobile No:	8347405029	107391409	
Date of Admission:	19/07/2024 11:56:21 AM		
Date of Discharge :	26/07/2024 09:02:00 AM		

ICD Code: ,C69.2  
ICD Description: Malignant neoplasm Retina

Diagnosis  
.RE GROUP E RB STAGE 3 A ( EXTRAOCULAR )  
LE WNL

Investigation	Systemic	.NIL SI	Ocular	.VA- RE- DENIES PL LE-CARDIFF @ 50 CM 6/15 IOP- RE - DIG LOW LE- 14 mmhg
---------------	----------	---------	--------	---

Treatment/Operative Procedure	Surgeon	.DR ANGKU	Surgery	→ .RE ENUCLEATION WITH PRIMARY IMPLANT UNDER GA ON STUMP - 10mm- SILICON IMPLANT - 20 mm → ANTERIOR CONJUNCTIVAL THICKENING NOTED SENT FOR HPE (E) EUA : WNL.
	Date	25/07/2024		

Condition at Discharge	Vision	ENUCLEATED EYE	IOP	ENUCLEATED EYE
	Anterior Seg.	.ENUCLEATED EYE	Posterior Seg.	.ENUCLEATED EYE

Advice During Discharge	Oral	→ SYP AUGMENTIN (228MG/5ML) 5 ML TDS X 5 days → SYP PCM (125MG/5ML) 6 ML SOS FOR PAIN → SYP DIGENE 1 TSP OD BPF X 5 days	Topical	(R) [E/D MILFLOX TDS E/O OCCUPOL TDS
	Follow Up	.WITH DR ANGKU IN OPD 38B AT 9 AM ON 2/8/24	Position	→ .COLLECT HPE REPORT FROM 7TH FLOOR PATH DEPT ON FOLLOW UP

2/8/24  
38B  
9am

AIIMS FREE GENERIC PHARMACY  
(✓) MEDICINE RECEIVED  
NAME: \_\_\_\_\_  
DATE: 26/7/24  
SIGN: \_\_\_\_\_

Prepared By: Dr. ~~Rayush Majumdar~~  
ANGKU  
SR.  
Signature Of Senior Resident  
Date & Time  
Dr. R.P. Centre for Ophthalmic Sciences  
All India Institute of Medical Sciences  
New Delhi-29

dated

R. P. Centre (Eye Centre)

General  
₹0

PHID: 107391409

Date: 18/07/2024

Doc No.: 20240090014523

Clinic No.: 2024/RB/75

ARBIT YADAV

4Y/M

S/O: ARBIT YADAV

Retinoblastoma-Dr. SR/JR  
RB-V-R.142-B

Unit-V

Room No.: 142 B

अनुभाग व दिन  
Section and Day V  
शुक्रवार व बुधवार  
Tuesday & Friday

कमरा नंबर  
Cabin No.

138

Address: ALLAHABAD, UTTAR PRADESH, INDIA

Mobile: 8347405029

स. बजाज का एकक  
Bajaj's Unit

रोगी का नाम Name of the Patient	पुत्र/पुत्री/पत्नी S/D/W	लिंग Sex	आयु Age	पता Address
------------------------------------	-----------------------------	-------------	------------	----------------

दिनांक DATE	निदान DIAGNOSIS
----------------	--------------------

18/7/2024

(R) EORB. E orbital expansion

(U) उपचार Treatment

cardiologist  
25/26  
cardiologist (os) 6/24

- No. of Chemo cycle - 05 (16/07/24)
- EBRT / LAC - None
- Last EVA done on 20/05/24

6/24 EOB

OSB Dr. Sumit

Adm. Date of EVA + Enucleation

Ward 1B  
7:30 AM

Adm. post chemo  
Admin

कृपया इस कार्ड को सुरक्षित रखें तथा अस्पताल में दिखाने के समय हर वक्त साथ लायें। Today only.

Kindly keep this

RPH-190724024 107391409

your follow-up visits.

1. धूम्रपान निषेध 2.

3. थूकिये नहीं

1. No Smoking

3. No Spitting



ArpitiYadav

(E9)

SR (Sumit)

R. P. Centre (Eye Centre)

UHID: 107391409

Dept. No: 20240050034523

Clinic. No.: 2024/RB/77

ARPIT YADAV

S/O: AJAY YADAV

4Y/M

General

Date: 13/06/2024

₹0

Retinoblastoma-Dr. SR/JR  
RETINOBLASTOMA  
UNDER UNIT V R.142

Unit-V

THU

Room No.: 142 B

Address: ALI AHABAD, UTTAR PRADESH, INDIA

Mobile: 8347405029



अनुभाग व दिन  
Section and Day  
मंगलवार व शुक्रवार  
Tuesday & Friday

V

कमरा नंबर  
Cabin No.

यूएचआईडी नं.

बजाज का एकक

UHID No.

Prof. M. S. Bajaj's Unit

रोगी का नाम Name of the Patient	पुत्र/पुत्री/पत्नी S/D/W	लिंग Sex	आयु Age	पता Address
------------------------------------	-----------------------------	-------------	------------	----------------

दिनांक DATE	निदान DIAGNOSIS
----------------	--------------------

उपचार Treatment

(R) - EORB

(L) - WNL

No. of chemo cycle :- 03 (29/5/24)

EBRT / LAC - NONE

Last EVA done on 20/05/24

Pt - uncooperative

Cpt did not bring MRI films



To come on Wednesday (19/6/24)  
(11 am)

Room No.

कृपया इस कार्ड को सुरक्षित रखें तथा अस्पताल में दिखाने के समय हर वक्त साथ लायें।

Kindly keep this Card safely and bring it on your follow-up visits.

1. धूम्रपान निषेध 2. कूड़ा कर्कट केवल कूड़ेदान में ही डालें 3. थूकिये नहीं
1. No Smoking 2. Use Dustbin 3. No Spitting

(53)

DR. B.R.A. IRCH, AIIMS, NEW DELHI  
 Reg. Date-27/03/2024  
 Clinic No. 2024/21841  
 UHID-107391409  
 Name ARPIT YADAV  
 S/O- AJAY YADAV  
 Sex/Age M/4Y  
 Room 13 (Shift Morning)  
 Address ALLAHABAD, UTTAR PRADESH, INDIA

अनुभाग व दिन  
 Section and Day  
 मंगलवार व शुक्रवार  
 Tuesday & Friday  
 V

कमरा नंबर  
 Cabin No.

राज का एकक  
 Unit

रोगी का नाम Name of the Patient	पुत्र/पुत्री/पत्नी S/D/W	लिंग Sex	आयु Age	पता Address
Arpit Yadav	M			

दिनांक DATE	निदान DIAGNOSIS
19/6/24	उपचार Treatment CS/I MRC by Dr. Reddy

→ Previous MRI 28 March 2024  
 → Current - 1st June 2024  
 - Significant ↑ in orbital mass compared to previous scans.  
 - Preseptal spec + Ant. orbital soft tissue enlargement  
 - To come for to Room no 1 at 2pm today.

कृपया इस कार्ड को सुरक्षित रखें तथा अस्पताल में दिखाने के समय हर वक्त साथ लायें।  
 Kindly keep this Card safely and bring it on your follow-up visits.  
 1. धूम्रपान निषेध 2. कूड़ा कर्कट केवल कूड़ेदान में ही डालें 3. थूकिये नहीं  
 1. No Smoking 2. Use Dustbin 3. No Spitting

9315475107  
Dhamade

RB/77/24

25B

# ब. रो. वि. कार्ड

R. P. Centre (Eye Centre)

General 20

Date 19/03/2024

RPC OPD - Dr. Neelam  
Pushkar

Unit-V

TUE, FRI

Room No.: 30

Address: ALLAHABAD, UTTAR PRADESH, INDIA  
Mobile 8347405029



अनुभाग व दिन  
Section and Day  
मंगलवार व शुक्रवार  
Tuesday & Friday

V

कमरा नंबर  
Cabin No.

SOC 1790/24

वै. जाज का एकक  
V's Unit

पता Address	आयु Age	लिंग Sex	S/D/W
----------------	------------	-------------	-------

दिनांक  
DATE

निदान  
DIAGNOSIS

(R) Extero Oculan

उपचार Treatment (MRI feeding)

no outward protrusion of right eye since 1 months sudden out-

It was apparently well till 2 year ago, then child developed sudden onset pain & followed which took some medicines (topical eye drops)

RB/25 (R) Physical eye

[ no outward protrusion ]

outward protrusion of

कृपया इस कार्ड को सुरक्षित रखें तथा अस्पताल में दिखाने के समय हर वक्त साथ लायें (R)

Kindly keep this Card safely and bring it on your follow-up visits.

- धूम्रपान निषेध 1. No Smoking
- कूड़ा कर्कट केवल कूड़ेदान में ही डालें 2. Use Dustbin
- थूकिये नहीं 3. No Spitting

25-26  
Caravan &  
MRI  
REC

No straining  
to neck/eyes  
bat